

Treatment of Idiopathic Gastroparesis With Injection of Botulinum Toxin Into the Pyloric Sphincter Muscle

Larry S. Miller, M.D., Gregory A. Szych, M.D., Steven B. Kantor, B.A., Matthew Q. Bromer, M.D., Linda C. Knight, Ph.D., Alan H. Maurer, M.D., Robert S. Fisher, M.D., and Henry P. Parkman, M.D.
Sections of Gastroenterology and Nuclear Medicine, Temple University School of Medicine, Philadelphia, Pennsylvania

OBJECTIVES: We aimed to determine if botulinum toxin injection into the pyloric sphincter improves gastric emptying and reduces symptoms in patients with idiopathic gastroparesis.

METHODS: Patients with idiopathic gastroparesis not responding to prokinetic therapy underwent botulinum toxin (80–100 U, 20 U/ml) injection into the pyloric sphincter. Gastric emptying scintigraphy was performed before and 4 wk after treatment. Total symptom scores were obtained from the sum of eight upper GI symptoms graded on a scale from 0 (none) to 4 (extreme).

RESULTS: Ten patients were entered into the study. The mean percentage of solid gastric retention at 4 h improved from $27 \pm 6\%$ (normal $< 10\%$) before botulinum toxin injection into the pylorus to $14 \pm 4\%$ ($p = 0.038$) 4 wk after treatment. The symptom score decreased from 15.3 ± 1.7 at baseline to 9.0 ± 1.9 ($p = 0.006$) at 4 wk, a $38 \pm 9\%$ decrease. Improvement in symptoms tended to correlate with improved gastric emptying of solids ($r = 0.565$, $p = 0.086$).

CONCLUSIONS: This initial pilot study suggests that botulinum toxin injection into the pylorus in patients with idiopathic gastroparesis improves both gastric emptying and symptoms. (Am J Gastroenterol 2002;97:1653–1660. © 2002 by Am. Coll. of Gastroenterology)

INTRODUCTION

Gastric emptying is a highly regulated process reflecting the integration of propulsive forces generated by proximal fundic tone and distal antral contractions with the resistance of the pyloric sphincter. Antral hypomotility is thought to be a major factor in gastroparesis (1, 2). Current treatment for gastroparesis employs prokinetic agents that increase antral contractility and accelerate gastric emptying (3). Unfortunately, many patients remain symptomatic despite prokinetic agents. In addition, prokinetic agents may produce side effects that limit or prevent their use.

Increased gastric outlet resistance due to pyloric dysfunction or pylorospasm has been described in gastroparesis, primarily the diabetic kind (4, 5). Only a few studies have been performed to see whether inhibition of the pyloric sphincter muscle accelerates gastric emptying (6–8). An orally administered smooth muscle relaxant acting systemically might decrease antral contractility, perhaps further delaying emptying (9). Thus, therapy directed to the pylorus alone might be effective and avoid systemic effects.

Botulinum toxin is an inhibitor of cholinergic neuromuscular transmission and has been used to treat spastic disorders of both striated and smooth muscles by local injection into affected muscles (10). Reports by several centers have demonstrated that injection of botulinum toxin directly into the lower esophageal sphincter (LES) in patients with achalasia reduces LES pressure and improves dysphagia (11–14). It may be possible to treat gastroparesis by decreasing pyloric resistance using botulinum toxin injected into the pyloric sphincter muscle. This has previously been suggested to accelerate gastric emptying in diabetic gastroparesis (7, 8). The aim of this study was to determine whether injection of botulinum toxin into the pylorus improves gastric emptying and reduces symptoms in idiopathic gastroparesis.

MATERIALS AND METHODS

Study Subjects

Patients with symptomatic idiopathic gastroparesis not responding to prokinetic therapy were offered enrollment in this open-label pilot trial of botulinum toxin injection into the pyloric sphincter. The study was approved by the Institutional Review Board of Temple University Health Center. These patients had known idiopathic gastroparesis, documented by prior gastric emptying scintigraphy and upper endoscopy, with symptoms of nausea, vomiting, and/or early satiety refractory to prokinetic agents. Patients were excluded if they 1) had a mechanical cause for delayed gastric emptying such as an active pyloric channel ulcer or gastric cancer, 2) had diabetes mellitus (type 1 or 2), 3) had a known coagulopathy, or 4) were pregnant or breast feeding.

Study Protocol

Patients were maintained on their prokinetic regimen, if any, before and after botulinum toxin injection. Patients completed a questionnaire grading eight different symptoms including postprandial fullness, early satiety, bloating, epigastric discomfort (an ache or discomfort after eating, poorly localized), epigastric pain (a sharp, easy to pinpoint pain after eating), postprandial nausea, belching after meals, and vomiting on a 5-point scale graded from 0 (none) to 4 (extreme). Total duration and the frequency of the symptoms were also recorded. This symptom questionnaire is similar to one used and validated to evaluate dyspeptic symptoms and the response to prokinetic treatment in patients with gastroparesis (15). A total symptom score was calculated as the sum of each of the eight individual symptom scores, with a maximum total being 32 (16). Symptom scores were obtained before treatment, at 2 and 4 wk after treatment, and then at monthly intervals for 5 months.

Patients then underwent combined solid-liquid gastric emptying scintigraphy. After an overnight fast, the patient consumed the test meal, consisting of an egg sandwich and 300 ml of water. This is the conventional test meal used for clinical evaluation at Temple University Hospital (16, 17). The scrambled eggs were labeled with 500 μ Ci of technetium Tc-99m sulfur colloid to measure gastric emptying of solids, and the water was mixed with 125 μ Ci of indium 111 pentetic acid to measure gastric emptying of liquids. Scintigraphic images were obtained at 0, 15, 30, 45, 60, 90, 120, 180, and 240 min after meal ingestion. Analysis of the gastric emptying data was performed as previously described (17). Regions of interest were drawn around the stomach for all images acquired. The geometric mean of the gastric counts was determined as the square root of the product of anterior and posterior counts at each imaging time. After correction for radionuclide decay, geometric mean gastric counts at each imaging time were expressed as a percentage of the maximal geometric mean counts at time zero. The percent retention at 2 and 4 h after meal ingestion for solids and 1 and 2 h for liquids were determined. Normal solid phase gastric emptying with this meal is $\leq 50\%$ retention at 2 h and $\leq 10\%$ at 4 h for Tc-labeled solids; normal liquid phase gastric emptying is $\leq 50\%$ retention at 1 h and $\leq 10\%$ retention at 2 h for In-labeled liquids (17).

If the gastric emptying was delayed, patients then underwent upper endoscopy with examination of the esophagus, stomach, and duodenum. If no structural abnormalities that could cause delayed gastric emptying were present, 1 ml containing 20 U of botulinum toxin type A (Botox, Allergan, Irvine, CA) was injected with a sclerotherapy needle into each of four quadrants of the pyloric sphincter under direct visualization. This total of 80 U of Botox is the same amount injected into the LES for achalasia (11–13). In many of the patients in this study, a fifth 1 ml (20 U) was used, raising the total amount of Botox injected to 100 U in 5 ml (13).

Patients were assessed for symptoms in follow-up at 2

and 4 wk after treatment, and observed thereafter at monthly intervals for 5 months. Follow-up consisted of scoring the same symptoms during the initial assessment. At the 4-wk visit, gastric emptying scintigraphy was repeated.

Data Analysis and Statistics

Data collected included the gastric retention of solids and liquids and the symptom scores. The symptom scores and gastric emptying scintigraphy results were compared before and 1 month after botulinum toxin injection in the same patients. Statistical analyses were performed using the paired Student's *t* test. The change in gastric emptying time activity curves was analyzed with two-way analysis of variance for repeated measures for the two factors, subject and time. The Pearson correlation coefficient was used to correlate the improvement in gastric emptying with the improvement in symptoms. Results are expressed as means \pm SEMs.

RESULTS

Ten patients with idiopathic gastroparesis entered the study. The patient characteristics are shown in Table 1. All patients were female, with an average age of 41 ± 5 yr (range = 19–70). The duration of gastroparesis averaged 4 ± 1 yr (range = 1–11).

Gastric Emptying

An example of the solid phase gastric emptying scintigraphy in an individual patient before and 4 wk after botulinum toxin injection into the pyloric sphincter is shown in Figure 1. Overall, for all 10 patients, the mean values for the gastric emptying time activity curves for solid and liquid phases before and 4 wk after botulinum toxin injection into the pylorus are shown in Figure 2. There was an improvement in gastric emptying of solids after botulinum toxin treatment, as indicated by the gastric retention for solids after botulinum toxin injection being significantly less than the gastric retention before injection (Fig. 2A). Before botulinum toxin injection into the pylorus, the mean percentage of solid retention at 4 h for the 10 patients was $27 \pm 6\%$ (normal $< 10\%$). Four weeks after injection, this decreased to $14 \pm 4\%$ ($p = 0.038$). The change in solid phase gastric emptying of the individual patients is shown in Figure 3A. Using the retention of solids at 4 h to assess gastric emptying, seven of the 10 patients had an improvement in gastric emptying at 4 wk after botulinum toxin injection, two patients had no change, and one patient had worsening of gastric emptying.

There was no significant improvement in gastric emptying of liquids after botulinum toxin treatment, as indicated by the gastric retention for liquids after botulinum toxin injection not differing significantly from the gastric retention before injection (Fig. 2B). The mean percentage of liquid retention at 2 h for the 10 patients before botulinum toxin injection was $27 \pm 3\%$ (Fig. 3B). Four weeks after

Table 1. Study Patient Characteristics

Patient	Age/ Gender	Medical/Surgical Conditions	Main Symptoms	Duration of Symptoms	Prior Treatments	Current Treatments
1	70/F	Laparoscopic Toupet for GERD	Nausea, early satiety, bloating, heartburn	4 yr	Metoclopramide, domperidone	Domperidone
2	43/F	Celiac disease, endometriosis	Abdominal pain, nausea, bloating	1.5 yr	Metoclopramide, cisapride, domperidone	None
3	40/F	Hypothyroidism, cholecystectomy	Nausea, abdominal pain	2 yr	Cisapride, erythromycin	Metoclopramide
4	23/F	GERD	Bloating, early satiety, heartburn	4 yr	Metoclopramide, cisapride	Metoclopramide
5	30/F	Endometriosis, GERD	Bloating, abdominal pain, heartburn	2 yr	Metoclopramide, domperidone	Domperidone
6	38/F	Hypothyroidism	Nausea, bloating, abdominal pain	10 yr	Metoclopramide, cisapride, erythromycin	Metoclopramide
7	68/F	Multiple sclerosis	Bloating, abdominal fullness	3 yr	Cisapride	None
8	33/F	Fibromyalgia, cholecystectomy	Nausea, bloating, early satiety, heartburn	3 yr	Metoclopramide	Metoclopramide
9	19/F	None	Nausea, fullness, bloating	1 yr	Metoclopramide, domperidone	Domperidone
10	44/F	GERD	Bloating, nausea, abdominal discomfort	11 yr	Metoclopramide, cisapride, domperidone	None

injection, it was $23 \pm 4\%$ ($p = 0.217$; *i.e.*, no significant change).

Symptoms

The total symptom score decreased from 15.3 ± 1.7 at baseline to 10.3 ± 1.9 ($p = 0.034$) and 9.0 ± 1.9 ($p = 0.006$) at 2 and 4 wk, respectively (Fig. 4). These represent $26 \pm 14\%$ ($p = 0.007$) and $38 \pm 9\%$ ($p = 0.002$) improvements of symptoms at 2 and 4 wk, respectively. Overall, nine of the 10 patients had improvement in the total symptom score. There was improvement in the following specific symptoms: postprandial abdominal fullness (in eight patients), bloating (seven patients), early satiety (five patients), epigastric discomfort (five patients), epigastric pain (four

patients), and postprandial nausea (four patients). As seen in Table 2, of the eight symptoms scored there were significant decreases in the symptom scores for postprandial fullness ($p = 0.009$), bloating ($p = 0.017$), and abdominal discomfort ($p = 0.042$) and a trend for nausea to be improved ($p = 0.068$).

Relationship of Improvement in Gastric Emptying to Improvement in Symptoms

The improvement in symptom scores 4 wk after botulinum toxin injection tended to correlate with the improvement in solid phase gastric emptying (at 2 h, $r = 0.580$, $p = 0.080$; at 4 h, $r = 0.565$, $p = 0.086$) but not at all with the change in liquid gastric emptying (at 2 h, $r = 0.112$, $p = 0.759$).

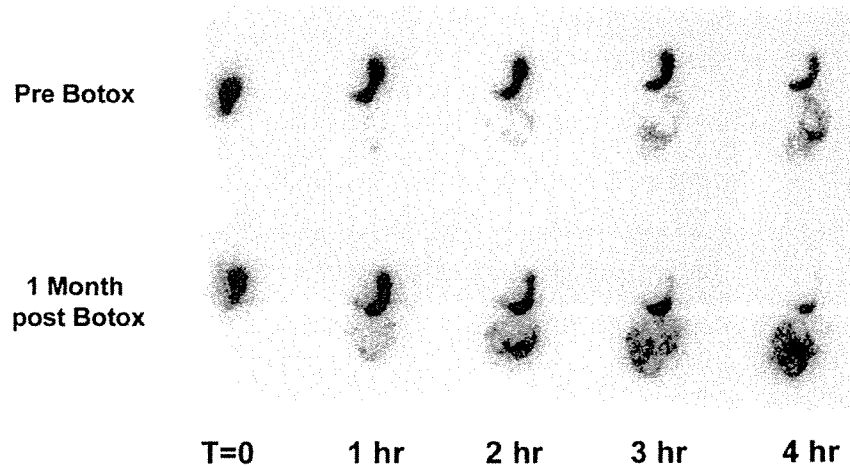


Figure 1. Example of improvement in solid phase gastric emptying after botulinum toxin injection into the pyloric sphincter in a single patient. Shown are the anterior images for the Tc-99m sulfur colloid solid phase marker at 0, 60, 120, and 240 min after meal ingestion. There was less gastric retention after botulinum toxin injection into the pylorus (64% retention at 2 h and 25% retention at 4 h) than at baseline before treatment (86% retention at 2 h and 49% at 4 h).

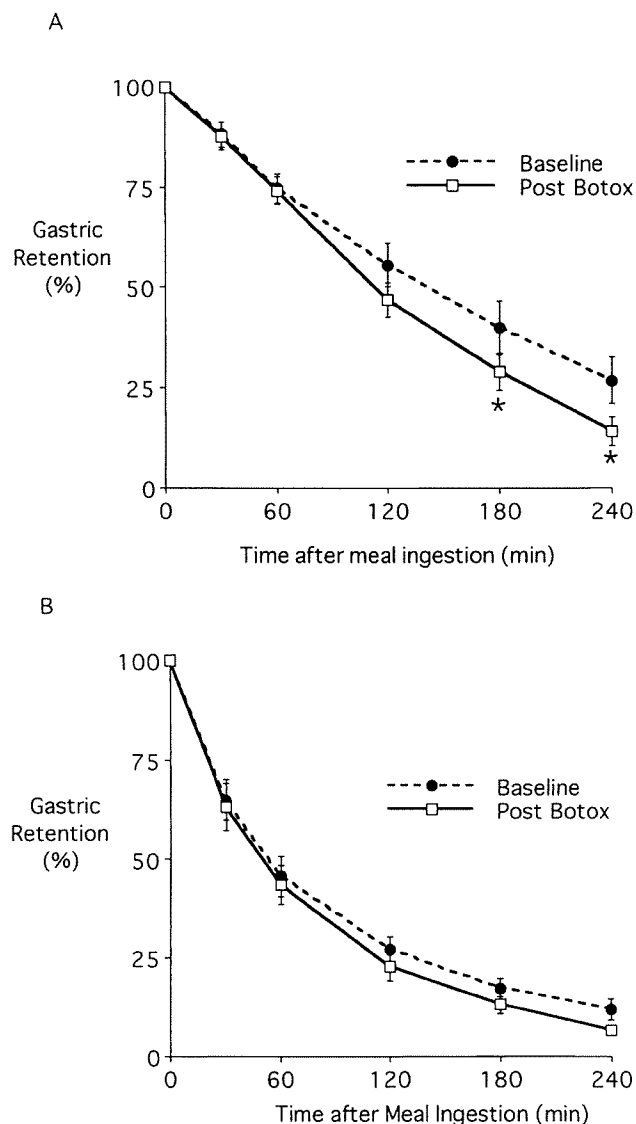


Figure 2. Gastric emptying time activity curves for solid (A) and liquid (B) phases at baseline before injection and 4 wk after botulinum toxin injection into the pylorus. Shown are the mean \pm SEM values for the 10 patients studied. (A) The gastric emptying time activity curve for solids showed significantly less gastric retention after botulinum toxin injection than before injection (two-way analysis of variance: $F = 3.292$, $p = 0.013$). The gastric retention was significantly less ($p < 0.05$) at 180 and 240 min after meal ingestion. (B) The gastric emptying time activity curve for liquids after botulinum toxin injection did not significantly differ from that before injection (two-way analysis of variance: $F = 0.440$, $p = 0.818$).

Symptom scores were reduced $46 \pm 11\%$ in the seven patients who had improvement in gastric emptying of solids. By comparison, the three patients with no change or worsening of gastric emptying experienced only a $22 \pm 11\%$ improvement in symptom scores ($p = 0.219$).

Long-term Follow-up

After the assessment 1 month after botulinum toxin injection, patients were observed clinically by their gastroenter-

ologists, who treated the patients symptomatically as needed. All 10 patients have been observed for more than 6 months (Table 3). Three of the 10 patients remain on prokinetic agents, whereas two are on no treatment. Five of the 10 patients have received a repeat botulinum toxin injection into the pylorus. The five patients who had repeat injections had an improvement in symptoms after the first injection, with return of their symptoms after 3–8 months. Each patient also had an improvement in symptoms in response to the second injection, a response lasting 2–6 months. Four of the five patients rated the response to the second injection the same as the first; one patient rated the second injection not as good as the first.

DISCUSSION

This open label study demonstrates that botulinum toxin injection into the pyloric sphincter muscle in patients with idiopathic gastroparesis improves gastric emptying and associated symptoms. The improvement in symptoms was moderate, averaging a 38% decrease in overall symptoms, with most patients still having some residual dyspeptic symptoms after treatment.

Botulinum toxin injection into the pylorus improved gastric emptying of solids. Using the percent retention of technetium-labeled solid food at 4 h after meal ingestion for the assessment of gastric emptying, seven of the 10 patients (70%) had improvement in gastric emptying after botulinum toxin injection. We and others have shown (17–19) that extending the radionuclide gastric emptying test to 4 h better separates patients with gastroparesis from those with normal gastric emptying. Interestingly, gastric emptying of liquids did not improve after botulinum toxin injection into the pyloric sphincter. The pylorus acts as a sieve to prevent larger particles from passing into the duodenum; it does not necessarily prevent liquid emptying, which is regulated by the gastroduodenal pressure gradient rather than pyloric resistance (20).

This study showed a reduction in dyspeptic symptoms after botulinum toxin injection into the pylorus. Furthermore, this improvement in symptoms tended to correlate with improvement in gastric emptying of solids. Interestingly, although gastric emptying improved with the treatment, it did not normalize in most patients despite an improvement in symptoms. In prior studies, there has been poor correlation between symptoms and delayed gastric emptying and between symptom improvement and accelerated gastric emptying with prokinetic treatment (21, 22). Stanghellini *et al.* (23) suggested that the correlation can be improved by evaluating not only the presence of symptoms but also the severity of symptoms. In the present study, both the presence of symptoms and their severity were included in the symptom scores. There were significant decreases in the symptom scores for postprandial fullness, bloating, and abdominal discomfort, and a trend for nausea to be improved.

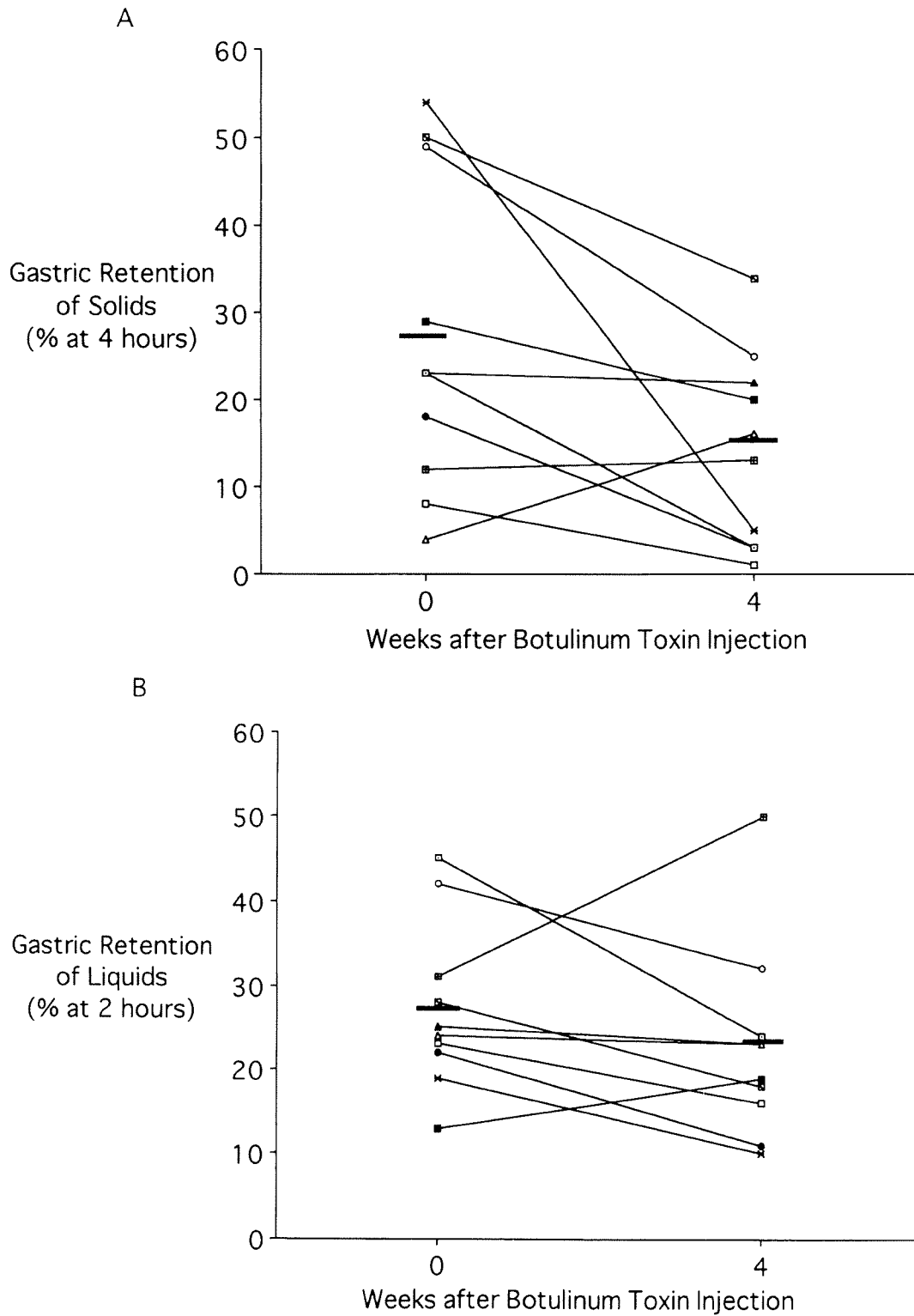


Figure 3. Effects of botulinum toxin injection into the pylorus on gastric emptying for each patient. (A) Solid phase gastric emptying. Shown is the percentage of retention of Tc-labeled solids at 4 h after meal ingestion. Seven of the 10 patients had an improvement in gastric emptying at 4 wk after botulinum toxin injection, two patients had no change, and one patient had worsening of gastric emptying. Before botulinum toxin injection into the pylorus, the mean percentage of solid retention at 4 h for the 10 patients was 27% (normal < 10%). Four weeks after injection, this decreased to 14%. (B) Liquid phase gastric emptying. Shown is the percentage of retention of In-labeled liquids at 2 h after meal ingestion. There was no significant effect of botulinum toxin injection on liquid phase gastric emptying. The mean percentage of liquid retention at 2 h for the 10 patients before botulinum toxin injection was 27%. Four weeks after injection, it was 23%. The bars represent the mean values of the 10 patients.

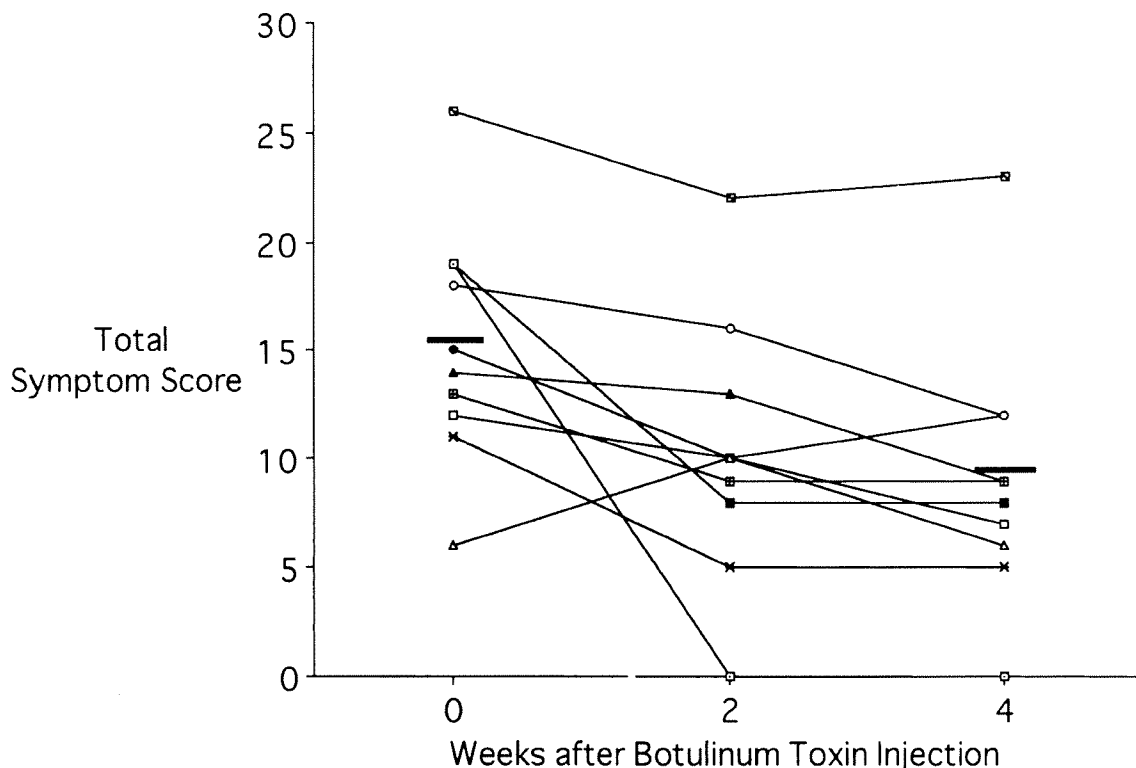


Figure 4. Improvement in symptoms after botulinum toxin injection into the pyloric sphincter. Shown are the total symptom scores for each patient before and at 2 wk and 4 wk after botulinum toxin treatment. Overall, nine of the 10 patients had improvement in symptoms. The mean total symptom score decreased from 15.3 at baseline to 10.3 and 9.0 at 2 and 4 wk, respectively. The bars represent the mean values of the 10 patients.

This study included only patients with idiopathic gastroparesis. Several other investigators have used botulinum toxin injection into the pylorus for treatment of insulin-dependent diabetic patients with gastroparesis. Lacy *et al.* (8) injected a larger dose (200 U) of botulinum toxin, with favorable although variable results. Ezzeddine *et al.* (24) reported that improvements in both gastric emptying and symptoms were observed when 100 U of botulinum toxin were injected into the pylorus in type 2 diabetic patients with gastroparesis. Sharma *et al.* (7) reported a favorable response in a case report using injection of 80 U of botulinum toxin into the pylorus. Several small studies have reported successful use of botulinum toxin injection into the pylorus for refractory postvagotomy pyloric spasm (two patients, 80 U) (25) and gas-bloat syndrome and dyspepsia after Nissen fundoplication (four patients, 100–200 U) (26).

Studies with botulinum toxin injection into the LES for achalasia have shown that the improvement in symptoms is temporary; in general, symptoms are improved for approximately 3 months (13, 14). Although side effects are rare, reports have been published suggesting that, in some patients, botulinum toxin injection may cause a tissue inflammatory reaction and may make subsequent Heller myotomy, if needed, more difficult. In addition, treatment with botulinum toxin into the LES may lead to heartburn and gastro-

esophageal reflux disease. In this study of botulinum toxin injection into the pylorus, patients were observed carefully for the initial month after treatment and for an additional 6 months after injection by telephone interview. A gradual return of symptoms to the baseline condition was observed. Patients generally required further treatment of their gastroparesis, such as cisapride on a compassionate basis or repeat injection of botulinum toxin into the pylorus. So far, no study patient has undergone implantation of a gastric elec-

Table 2. Symptomatic Response to Botulinum Toxin Injection (BTI) in the Pylorus for Idiopathic Gastroparesis

Symptom	Before	4 Weeks After BTI	<i>p</i>
Postprandial fullness	2.8 ± 0.2	1.6 ± 0.3	0.009
Postprandial bloating	2.6 ± 0.2	1.5 ± 0.3	0.017
Postprandial abdominal discomfort	2.1 ± 0.5	1.1 ± 0.4	0.042
Early satiety	1.9 ± 0.4	1.5 ± 0.2	0.104
Postprandial epigastric pain	1.7 ± 0.5	1.0 ± 0.4	0.111
Postprandial nausea	2.2 ± 0.5	1.3 ± 0.4	0.068
Belching after meals	1.3 ± 0.3	0.8 ± 0.3	0.177
Vomiting	0.8 ± 0.4	0.6 ± 0.4	0.168
Total symptom score	15.3 ± 1.7	9.1 ± 1.0	0.006

Symptoms were graded by the 10 patients on a 5-point scale graded from 0 (none) to 4 (extreme). Results expressed as means ± SEMs.

Table 3. Patient Outcome After Botulinum Toxin Injection (BTI) Into the Pylorus

Patient	Amount of Botox Injected	Short Term (4 wk) Response	Long Term (6 mo) Outcome	Subsequent Therapy after Initial BTI	Duration of Follow-Up
1	80 U	Improvement	Improvement	Repeat BTI into pylorus at 9 mo after initial BTI	14 mo
2	100 U	Improvement	No change	Repeat BTI into pylorus at 8 mo after initial BTI	11 mo
3	80 U	Improvement	Improvement	Repeat BTI into pylorus at 4.5 mo after initial BTI	7 mo
4	100 U	Improvement	Improvement	Continues on metoclopramide	12 mo
5	100 U	Improvement	Improvement	Remains on domperidone	7 mo
6	80 U	Improvement	Improvement	Repeat BTI into pylorus at 11 mo after initial BTI	13 mo
7	80 U	No change	No change	No therapy for gastroparesis	7 mo
8	80 U	Improvement	No change	No therapy for gastroparesis	6 mo
9	100 U	Slight improvement	NA	Started cisapride compassionate use at 2 mo	8 mo
10	100 U	Improvement	NA	Repeat BTI into pylorus at 5 mo after initial BTI	8 mo

tric stimulator, which is another treatment for refractory gastroparesis (27). Thus, botulinum toxin injection into the pylorus may provide short-term moderate symptomatic improvement and acceleration of gastric emptying. However, it is not likely that long-term control can be achieved with a single injection.

This study was an initial pilot study. Questions remain about the clinical use of botulinum toxin injection for the treatment of gastroparesis. First, the role of relaxing the pylorus in accelerating gastric emptying needs to be further studied. Gastric emptying involves a series of coordinated events including fundic relaxation and contraction, antral contraction, pyloric relaxation, and duodenal contraction. Antral contractility correlates with gastric emptying of solids (28). Recent physiological studies have shown the importance of the pylorus in regulating gastric emptying (5). Although some studies have suggested that pyloromyotomy may not affect gastric emptying (29), other studies have shown it to be beneficial in patients with diabetic gastroparesis (6) and in preventing gastric stasis after a vagotomy (20). Second, the dose of botulinum toxin used in this study (80–100 U) may be too low to fully relax the pylorus. The dose of botulinum toxin chosen was based on previous studies in achalasia (11–13). Lacy *et al.* (8) injected higher total doses (200 U) of botulinum toxin into the pylorus, with variable results. Third, gastric dumping symptoms have been reported after surgical pyloromyotomy due to the decreased pyloric resistance to large particles of solid food (20). This did not occur in this study after botulinum toxin injection into the pylorus. Fourth, botulinum toxin injection into the pylorus could diffuse into the antrum and decrease antral contractility. This could potentially further delay gastric emptying and worsen the patient's symptoms. In our study, only one patient had worsening of delayed gastric emptying after botulinum toxin injection. Future studies using endoscopic ultrasound guidance for injection into the pylorus might prevent this theoretical adverse event; endoscopic ultrasound guidance has been used for injecting botulinum toxin into the LES in achalasia (30). Finally, patients with idiopathic gastroparesis likely represent a heterogeneous group with different pathophysiological abnormali-

ties; some groups may respond to botulinum toxin injection and others may not.

Because this was an open label pilot study, there is a potential for study bias. The symptomatic improvement of the patients in this open label study may represent a placebo response. Subsequent studies should evaluate botulinum toxin injection into the pylorus for gastroparesis using a randomized, controlled, double blind design comparing botulinum toxin to placebo (saline sham) injections, similar to the protocol previously employed by Pasricha *et al.* to study achalasia (12).

In conclusion, botulinum toxin injection into the pyloric sphincter muscle in patients with idiopathic gastroparesis accelerated gastric emptying and reduced dyspeptic symptoms of gastroparesis. This study suggests that the majority of patients with idiopathic gastroparesis will have a modest but significant short-term improvement in gastric emptying and symptoms after botulinum toxin injection into the pylorus.

ACKNOWLEDGMENT

This study was supported in part by a National Institutes of Health (NIH) Midcareer Investigator Award in Patient-Oriented Research to H.P.P. (NIH K24 DK02921) and by the NIH General Clinical Research Centers Program of the National Center for Research Resources (RR00349). Study medication was provided by Allergan, Inc.

Reprint requests and correspondence: Henry P. Parkman, M.D., Gastroenterology Section, Parkinson Pavilion, 8th Floor, Temple University Hospital, 3401 North Broad Street, Philadelphia, PA 19140.

Received Nov. 6, 2001; accepted Mar. 21, 2002.

REFERENCES

1. Malagelada J-R, Rees WDW, Mazzotta LJ, Go VLW. Gastric motor abnormalities in diabetic and postvagotomy gastroparesis: Effect of metoclopramide and bethanechol. *Gastroenterology* 1980;78:286–93.

2. Camilleri M, Brown ML, Malagelada J-R. Relationship between impaired gastric emptying and abnormal gastrointestinal motility. *Gastroenterology* 1986;91:94-9.
3. Chey WD, Hasler WL. Gastrointestinal motility disorders and gastroparesis. In: Brandt LJ, ed. *Clinical practice of gastroenterology*. Philadelphia: Churchill Livingstone, 1999:235-49.
4. Mearin F, Camilleri M, Malagelada J-R. Pyloric dysfunction in diabetics with recurrent nausea and vomiting. *Gastroenterology* 1986;90:1919-25.
5. Fraser R, Horowitz M, Maddox A, Dent J. Organization of antral, pyloric and duodenal motility in patients with gastroparesis. *J Gastrointest Motil* 1993;5:167-75.
6. Abouezzi ZE, Melvin WS, Ellison EC, Schirmer WJ. Functional and symptomatic improvement in patients with diabetic gastroparesis following pyloroplasty. *Gastroenterology* 1998;114:A1374 (abstract).
7. Sharma VK, Glassman SB, Howden CW, Vasudeva R. Pyloric intrasphincteric botulinum toxin in a patient with diabetic gastroparesis. *Am J Gastroenterol* 1998;93:456 (abstract).
8. Lacy BE, Schettler-Duncan VA, Crowell MD. The treatment of diabetic gastroparesis with botulinum toxin. *Am J Gastroenterol* 2000;95:2455-6 (abstract).
9. Hasler WL. Are things looking up for the treatment of gastroparesis? Sildenafil in animal models of diabetic gastropathy. *Gastroenterology* 2001;120:576-8.
10. Jankovic J, Brin MF. Therapeutic uses of botulinum toxin. *N Engl J Med* 1991;324:1186-94.
11. Pasricha PJ, Ravich WJ, Hendrix TR, et al. Treatment of achalasia with intrasphincteric injection of botulinum toxin: A pilot trial. *Ann Intern Med* 1994;121:590-1.
12. Pasricha PJ, Ravich WJ, Hendrix TR, Kaloo AV. Intrasphincteric botulinum toxin for the treatment of achalasia. *N Engl J Med* 1995;332:774-8.
13. Fishman VM, Parkman HP, Schiano T, et al. Symptomatic improvement in achalasia after botulinum toxin injection of the lower esophageal sphincter. *Am J Gastroenterol* 1996;91:1724-30.
14. Pasricha PJ, Rai R, Ravich WJ, et al. Botulinum toxin for achalasia: Long-term follow-up and predictors of outcome. *Gastroenterology* 1995;110:1410-5.
15. Talley NJ, Verlinden M, Snape W, et al. Failure of a motilin receptor agonist (ABT-229) to relieve the symptoms of functional dyspepsia in patients with and without delayed gastric emptying: A randomized double-blind placebo-controlled trial. *Aliment Pharmacol Ther* 2000;14:1653-61.
16. Parkman HP, Miller LS, Knight LC, et al. Electrogastrography and gastric emptying scintigraphy are complementary for assessment of dyspepsia. *J Clin Gastroenterol* 1997;24:214-9.
17. Guo J-P, Maurer AH, Urbain J-L, et al. Extending gastric emptying scintigraphy from two to four hours detects more patients with gastroparesis. *Dig Dis Sci* 2001;46:24-9.
18. Tougas GH, Eaker EY, Abell TL, et al. Assessment of gastric emptying using a low fat meal: Establishment of international control values. *Am J Gastroenterol* 2000;95:1456-62.
19. Camilleri M, Hasler W, Parkman HP, et al. Measurement of gastroduodenal motility in the GI laboratory. *Gastroenterology* 1998;115:747-62.
20. Malagelada J-R, Azpiroz F, Mearin F. Gastrointestinal motor function in health and disease. In: Sleisenger MH, Fordtran JS, eds. *Gastrointestinal disease—pathophysiology/diagnosis/management*. Philadelphia: WB Saunders, 1993:486-508.
21. Talley NJ, Shuter B, McCrudden G, et al. Lack of association between gastric emptying of solids and symptoms in nonulcer dyspepsia. *J Clin Gastroenterol* 1989;11:625-30.
22. Koch KL, Stern RM, Stewart WR, Vasey MW. Gastric emptying and gastric myoelectric activity in patients with diabetic gastroparesis. Effect of long-term domperidone treatment. *Am J Gastroenterol* 1989;84:1069-74.
23. Stanghellini V, Tosetti C, Paternico A, et al. Risk indicators of delayed gastric emptying of solids in patients with functional dyspepsia. *Gastroenterology* 1996;110:1036-42.
24. Ezzeddine DZ, Jit R, Katz N, et al. Pyloric injection of botulinum toxin for treatment of diabetic gastroparesis. *Gastrointest Endosc* 2001;53:AB63 (abstract).
25. Wiesel PH, Schneider R, Dorta G, et al. Botulinum toxin for refractory postoperative pyloric spasm. *Endoscopy* 1997;29:132.
26. De Looze D, Verdier H, Elewaut A. Intrapyloric injection of botulinum toxin for treating post-Nissen's dyspepsia and gas-bloat syndrome. *Gastroenterology* 1999;116:A145 (abstract).
27. McCallum R, Abell TL, Hocking M, et al. Results of long-term high frequency gastric electrical stimulation (GES) for treatment of gastroparesis refractory to standard medical therapy. *Gastroenterology* 2001;120:A98 (abstract).
28. Camilleri M, Malagelada J-R, Brown ML, et al. Relation between antral motility and gastric emptying of solids and liquids in humans. *Am J Physiol* 1985;249:G580-5.
29. Sun WM, Doran SM, Jones KL, et al. Long-term effects of pyloromyotomy on pyloric motility and gastric emptying in humans. *Am J Gastroenterol* 2000;95:92-100.
30. Hoffman BJ, Knapple WL, Bhutani MS, et al. Treatment of achalasia by injection of botulinum toxin under endoscopic ultrasound guidance. *Gastrointest Endosc* 1997;45:77-9.