

VIEWPOINTS IN DIGESTIVE DISEASES

Pitfalls in the Analysis of Electrogastrographic Recordings

MARC A. M. T. VERHAGEN,* LEONARD J. VAN SCHELVEN,† MELVIN SAMSOM,*
and ANDRÉ J. P. M. SMOUT*

*Gastrointestinal Research Unit, Department of Gastroenterology, and †Department of Biomedical Engineering, University Hospital Utrecht, Utrecht, The Netherlands

Electrogastrography (EGG) is a noninvasive method to study gastric myoelectrical activity in humans. Because frequency characteristics are the most reliable parameters and visual analysis of the EGG recordings is notoriously difficult, automated frequency analysis, especially running spectrum analysis, is often used. However, EGG frequency spectra can be misinterpreted easily. Movement artifacts and noise from various sources can result in abnormal frequency spectra with significant power in the low-frequency and high-frequency range, or even make the EGG completely uninterpretable. Signals that differ from a sinusoid waveform have harmonics in the high-frequency range of the spectrum and may be interpreted as abnormal. Visual inspection of raw signals and frequency spectra remains essential in the analysis of EGG signals. The value of computerized analysis should not be overrated. EGG is an important research tool, but a clinical role still needs to be established.

Electrogastrography (EGG) is the technique of recording gastric myoelectrical activity from cutaneous electrodes. The first electrogastrogram in humans was described in 1921 by Alvarez,¹ but relatively little progress was made until the last two decades. Improved recording techniques and automated methods for EGG analysis have been developed, contributing to the increasing popularity of the technique. Abnormalities in the EGG have been reported in gastroparesis, gastric surgery, nausea and vomiting, motion sickness, and various other clinical disorders.²⁻⁴ However, no studies provide convincing evidence that EGG can replace validated diagnostic techniques.

Commercially available hardware and software have made recording and analysis of EGG signals easy to perform. With modern computers, the analysis of lengthy EGG recordings takes relatively little time and a multitude of parameters^{5,6} can be calculated simply. However, along with the advent of fully automated analysis

techniques, the danger of erroneous interpretation of the end results crept in.

The analysis of EGG signals and pitfalls in the interpretation of the results will be discussed in this review.

Gastric Myoelectrical Activity

The electrical activity of the stomach consists of rhythmic waves of depolarization and repolarization of the smooth muscle cells. These waves originate from a pacemaker area along the major curvature (Figure 1) and propagate aborally with increasing velocity, with intervals of approximately 20 seconds in humans.⁷⁻¹¹ This activity is always present and is not directly associated with contractions, but it determines the spatial and temporal organization of gastric contractions.¹² At any time, 2-3 depolarization fronts are present simultaneously (Figure 1).¹³

Contractions of the stomach are associated with a lengthening of the plateau phase that follows depolarization, with spike activity superimposed on it.^{7,13} When studied with extracellular electrodes, the depolarization phase is recorded as so-called "electrical control activity" and the contraction related activity as "electrical response activity."¹² In humans, both types of electrical activity can be measured by serosal electrodes^{8,9,11,14,15} and mucosal electrodes,^{9,16-19} but the invasiveness of these techniques limits their use.

EGG

When cutaneous electrodes are used to pick up gastric myoelectrical activity, a sinusoidal wave is recorded, which is believed to reflect the overall electrical activity of the stomach, i.e., of the whole gastric area with electrical control and electrical response activity.^{2,13} It has been shown that the dominant frequency of the signal

Abbreviations used in this paper: cpm, cycles per minute; EGG, electrogastrography; FFT, fast Fourier transform.

© 1999 by the American Gastroenterological Association
0016-5085/99/\$10.00

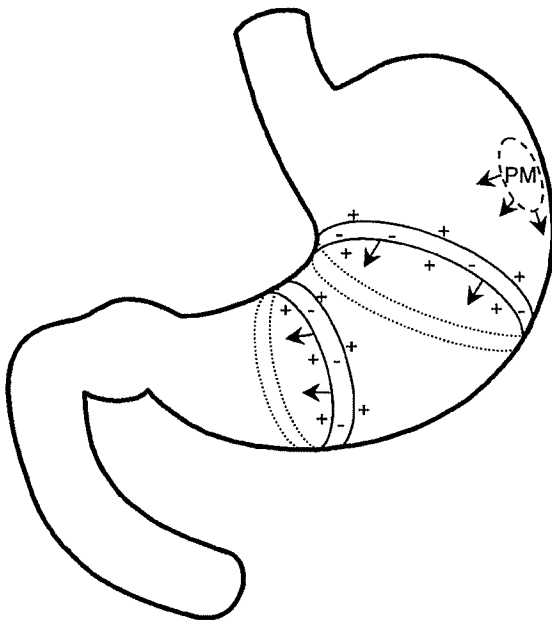


Figure 1. Schematic representation of gastric myoelectrical activity. Depolarization fronts, originating from a pacemaker area (PM), propagate aborally toward the pylorus. Several depolarization fronts are present simultaneously.

recorded with cutaneous abdominal electrodes is identical to the frequency of the electrical activity of the stomach.^{1,8,13,15-17,20-22} However, there are major limitations to cutaneous recording of gastric myoelectrical activity compared with recordings directly from the gastric wall. In "internal" recordings the electrical activity of a relatively small area of the gastric wall is recorded, resulting in sharp positive and negative deflections.^{2,13,15} The cutaneous electrodes, however, "see" the gastric myoelectrical activity of the entire stomach, containing several electrical fronts, resulting in a sinusoid waveform of the signal.^{2,13,15,22-27} Therefore, not all the details of gastric myoelectrical activity, such as spike activity, electrical uncoupling in a small portion of the stomach, or variable intervals between consecutive depolarization waves, are visible in EGG.^{15,26} The usual practice is to record several EGG signals simultaneously from standardized positions on the upper abdomen and to select the signal with the highest amplitude for further analysis.²⁸

Spectral Analysis of EGG Signals

The cutaneously recorded gastric signal is relatively weak and is often difficult to distinguish from background noise.^{2,23,29} Quantification of frequency and amplitude by visual analysis is therefore very difficult and prone to observer bias.^{2,5,17,30} To provide a more objective quantification, several methods for automated analysis of

EGG signals have been developed,^{8,23} but spectral analysis is most frequently used.^{2,23,31}

An example of calculation of a frequency spectrum of a sine wave of 3 cycles per minute (cpm), using the fast Fourier transform (FFT), is shown in Figure 2. Because an abrupt ending of the signal leads to "leakage" of power of the main peak into additional lobes (Figure 2B), a Hamming window is applied (Figure 2C), which causes a relative attenuation of both edges of the signal stretch (Figure 2D). After applying a Hamming window, the resulting frequency spectrum shows a single peak at 3 cpm (Figure 2E). The vertical axis of the spectrum is linearly proportional to the squared amplitude of the signal and is called the "power."

Apart from the possibility to quantify frequencies and amplitude, frequency analysis can also detect frequencies that are not clearly visible in the raw EGG signal. When 2 peaks are present in the frequency spectrum, this might represent a change in frequency (Figure 3A) or a "mixture" of 2 frequencies (Figure 3B). In the latter case, both frequencies are difficult to recognize by visual analysis of the raw signal.

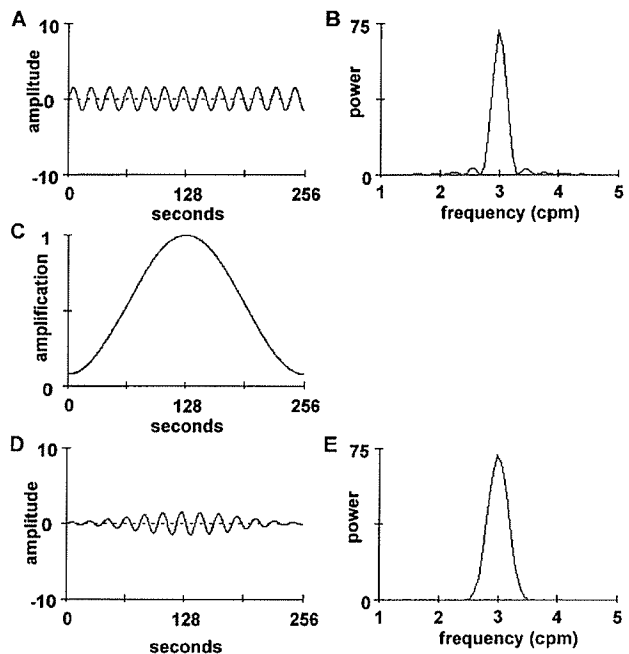


Figure 2. Calculation of a frequency spectrum. Power is given in arbitrary units. (A) A 256-second signal stretch of a sine wave with a frequency of 3.0 cpm. (B) Frequency spectrum of the signal in A, calculated by an FFT without applying the Hamming window. Power of the main frequency (3 cpm) "leaks" into additional lobes in the frequency spectrum. (C) The Hamming window that is applied on the signal before an FFT is performed. (D) Shape of the 256-second signal stretch after application of the Hamming window. The 2-minute period in the center of the 256-second signal stretch accounts for most of the power in the frequency spectrum. (E) Frequency spectrum of the signal in Figure 1, calculated by an FFT after applying the Hamming window.

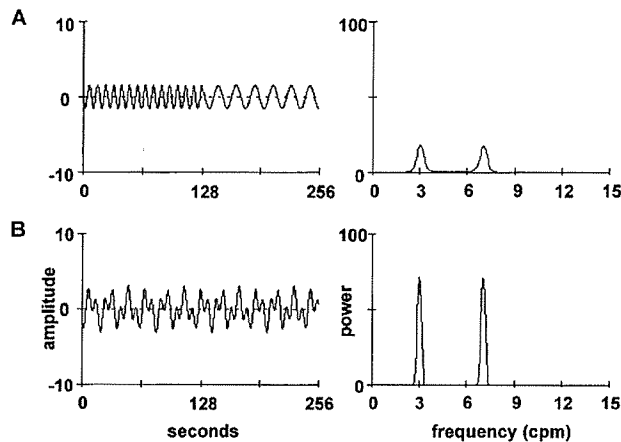


Figure 3. Recognition of more than 1 frequency in the EGG. (A) Signal of 3.0 cpm is interrupted by a signal of 7.0 cpm. The frequency spectrum displays 2 peaks. (B) Signal of 3.0 cpm and signal of 7.0 cpm combined during the entire recording. The raw signal is difficult to interpret, but the frequency spectrum displays peaks at both frequencies. The power in the spectrum is higher because both frequencies are present continuously.

Of the available methods for spectral analysis of EGG signals,^{21,23,31,32} running spectrum analysis has become the standard.^{2,21} In running spectrum analysis, an FFT is applied to consecutive 256-second signal stretches that have an overlap of approximately 75%. This results in a series of minute by minute frequency spectra that can be presented in pseudo-3-dimensional plots or in greyscale plots, giving an overview of the changes in frequency and amplitude of the EGG in time (Figure 4).

Interpretation of Frequency Spectra

Power

Meal ingestion results in an increase in EGG amplitude.^{28,33} Smout et al.¹³ showed that in dogs changes in EGG amplitude run parallel with the changes in the intensity of electrical response activity and antral contraction amplitude. Because this phenomenon was observed not only in the postprandial but also the interdigestive state, this observation suggested that EGG

amplitude is not solely determined by the distance of the signal source to the electrode.¹³ In contrast, Brown et al.²⁰ suggested that a closer proximity of the electrodes to the stomach is responsible for the postprandial increase in amplitude. This was confirmed by Mintchev et al.,²² who showed that the amplitude of the EGG increases with decreasing distance between the recording electrode and the stomach. Thus, alterations in amplitude should be interpreted with some reticence because they may be related to both gastric contractile activity and to changes in the position of the stomach. Computer models have suggested that the amplitude of the signal is also related to the propagation velocity of depolarization waves in the stomach³⁴ and that a decreased amplitude can be caused by uncoupling of electrical control activity.³⁵ Identification of the phases of the interdigestive migrating complex in humans from the EGG appeared not to be possible.³⁶

A frequently calculated parameter is the postprandial to fasting power ratio.^{6,33,37} The power in the normal frequency range of the EGG usually increases more than 2-fold after meal ingestion. A power ratio lower than 1 is unusual and may indicate an abnormal gastric response to meal ingestion.³⁸ However, the physiological significance of changes in power is still unclear.

Frequency

The normal frequency of gastric myoelectrical activity in healthy humans is approximately 3 cpm. Values for the normal range vary slightly between laboratories, but usually frequencies between 2.6 and 3.7 cpm are considered normal.^{2,5,6,39} Signals with a frequency greater than 10 cpm most likely originate from respiration or from electrical activity of other parts of the gut, especially the small bowel.^{2,5,20,21,23,30,40} In the literature an increasing tendency toward "diagnosing" dysrhythmias from EGG spectra is apparent. An often chosen approach is to sum all powers in certain frequency ranges and to calculate the distribution of the powers over

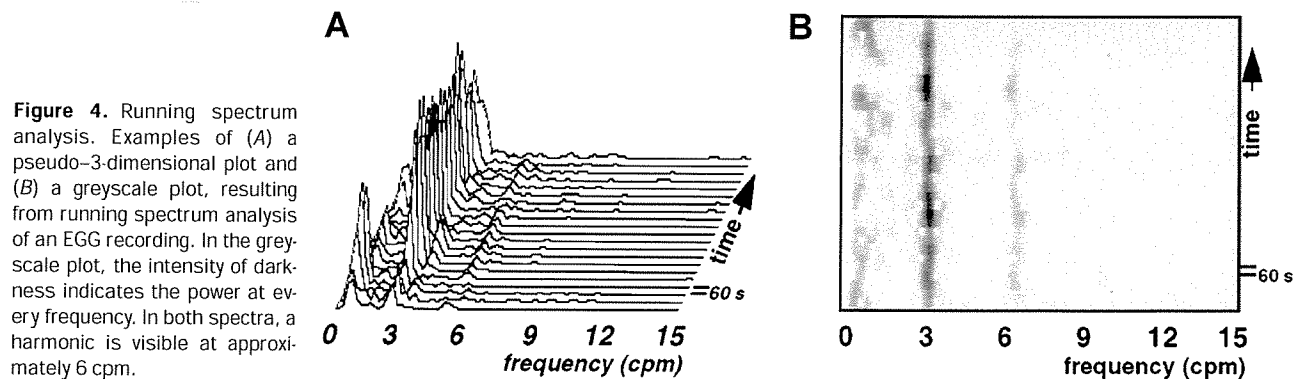


Figure 4. Running spectrum analysis. Examples of (A) a pseudo-3-dimensional plot and (B) a greyscale plot, resulting from running spectrum analysis of an EGG recording. In the greyscale plot, the intensity of darkness indicates the power at every frequency. In both spectra, a harmonic is visible at approximately 6 cpm.

these ranges.^{39,41,42} Abnormal rhythms (dysrhythmias) are considered present when too much power is present in the low-frequency range (bradygastrias) or in the high-frequency range (tachygastrias).^{39,41,42} This approach is debatable because several mechanisms may lead to frequency spectra with high powers in either the low-frequency range or the high-frequency range, in the absence of abnormal gastric myoelectrical activity.

Erroneous Diagnosis of Frequencies in the Low-Frequency (Bradygastria) Range

Frequency spectra of EGG signals often show an exponential increase of power toward the very low frequency range (<1 cpm). These frequencies are not likely to originate from the stomach. No reports of frequencies <1 cpm recorded directly from the gastric wall can be found in literature,^{5,6,41} and no other documented sources within the human body are likely to generate these signals. It is far more likely that the ultralow frequency components of EGG signals are caused by factors inherent to the EGG recording technique. One of them is low-frequency electrode noise, caused by spontaneous variations in electrode potential.^{5,23} Another possible source is movement artifacts,^{5,15,16,30,43} consisting of sudden upward or downward deflections in the EGG signal. As shown in Figure 5, computer simulations show that movement artifacts and drift of the signal lead to a low-frequency component in the frequency spectrum. Most EGG recording systems employ high-pass filters with a cutoff frequency at 0.01 Hz (corresponding to 0.6 cpm) that let most of the frequencies <1 cpm through.

Erroneous Diagnosis of Frequencies in the High-Frequency (Tachygastria) Range

During tachygastrias, abnormal high-frequent electrical activity originates in an ectopic focus in the gastric wall. In the presence of tachygastrias, the stomach is mechanically inactive.^{6,17,44} Although there is ample evidence that tachygastrias can be detected electrogastrographically,^{15,17} some caveats should be considered. Frequency analysis is based on the fact that all signals can be constructed from a series of sine waves. The Fourier transform unravels any signal into its composing sine waves. For a nonsinusoidal periodical signal, the frequency spectrum will show harmonics: peaks at exact multiples of the fundamental frequency (Figure 6). It is uncertain whether waveform, as expressed by the presence of harmonics in the frequency spectrum, provides relevant information on gastric (myoelectrical or contractile) activity. The EGG waveform is influenced by the position^{45,46} and the surface area^{45,47} of the cutaneous electrodes. It has been suggested that the EGG waveform is

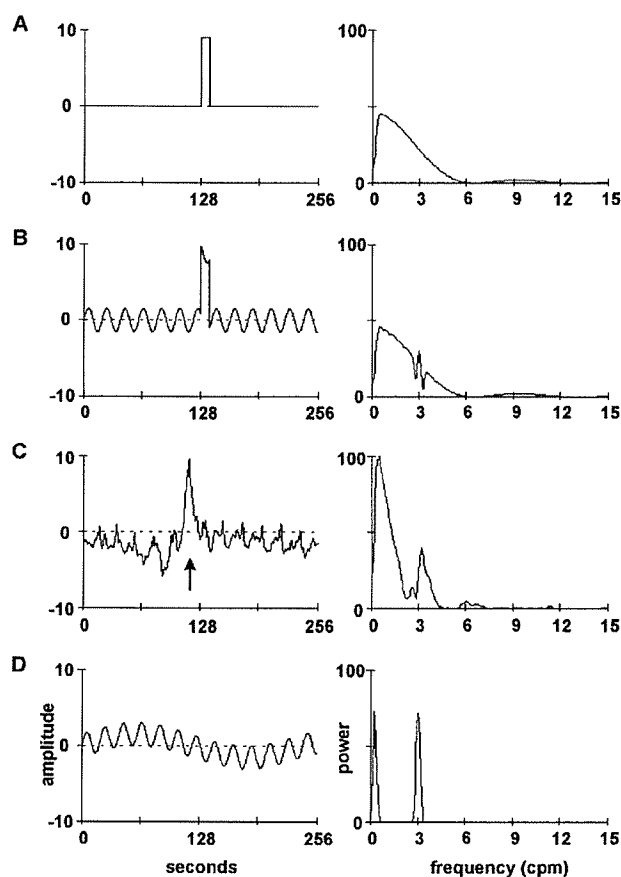


Figure 5. Signals that result in a power increase in the bradygastria range; 256-second signal stretches and their frequency spectra. (A, B, and D) Computer-generated signals and (C) a human EGG recording. (A) Computer-generated rectangular artifact. (B) Combination of signals in Figure 2A (3.0 cpm) and Figure 5A. (C) EGG recording showing a normal frequency with a sudden increase caused by a movement artifact (arrow). (D) Effect of low frequency drift (1 cpm) on the signal in Figure 2A (3.0 cpm).

related to the propagation of depolarization fronts,^{27,35} but this could not be confirmed by others.^{22,48,49} The presence of harmonics in the spectrum indicates that the signal shape is not sinusoid but does not indicate the presence of abnormal high-frequent gastric myoelectrical activity or tachygastrias.^{5,15,23} Because harmonics may lay within the high-frequency range of the frequency spectrum, they lead to an increased power content within that range and thus to an erroneous diagnosis of tachygastria.

As demonstrated by computer simulation in Figure 7A, signals in the high-frequency range can also be brought about by series of movement artifacts. When these occur in a single signal stretch, they result in a series of peaks in the frequency spectrum at regular intervals, in which the original signal cannot be recognized (Figure 7A and B). These episodes can be easily recognized by visual inspection of raw signals and frequency spectra and should be disregarded in the analysis.

Respiration may also be reflected in the tachygastria

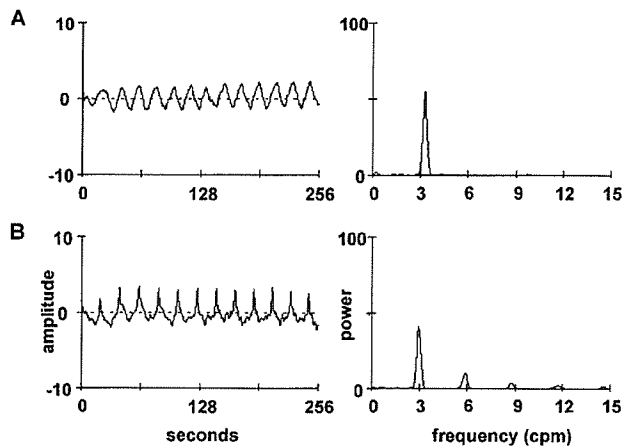


Figure 6. Harmonics; 256-second signal stretches and their frequency spectra. (A) Normal EGG recording with a sinusoidal shape, with no harmonics in the spectrum. (B) Normal EGG recording with a nonsinusoidal shape. Besides the dominant peak at 3 cpm, harmonics are visible at 6, 9, 12, and 15 cpm.

range of the EGG. Because of constant variation in the frequency of respiration, the associated peaks in the frequency spectra are wide and blunt and can be easily recognized as such. The respiration frequency is usually >12 cpm. However, in sleeping subjects respiratory frequency can be low (<12 cpm) and stable for prolonged periods of time.

It has been shown recently in dogs that abnormal frequencies in the EGG may result from electrical uncoupling of gastric myoelectrical activity.²⁶ In particular, some of the high frequencies observed in cutaneous recordings during severe uncoupling were not recorded in one of the serosal recordings.²⁶

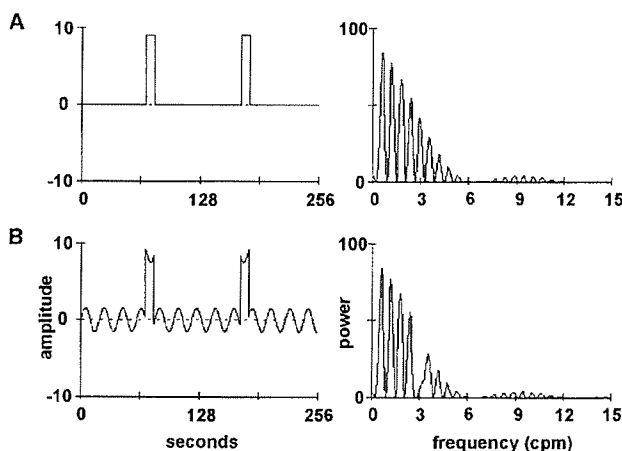


Figure 7. Movement artifacts; 256-second signal stretches and their frequency spectra. (A) Computer-generated signal with 2 consecutive rectangular artifacts. The frequency spectrum displays many peaks throughout the spectrum. (B) Combination of signals in Figure 2A (3.0 cpm) and Figure 7A.

Recommendations for Interpretation of EGG Frequency Spectra

As outlined above, a diagnosis of bradygastria, normogastria, or tachygastria cannot be made simply on the basis of the distribution of power in the EGG spectrum. Instead, criteria that give credit to the physiological background of the recorded signals should be applied. Dysrhythmias should be quantified as a percentage of time during which they are present, or by the percentage of frequency spectra in which they occur in the running spectrum analysis, and not as a percentage of the total power.^{6,39} In our opinion it is important to distinguish between "definite" and "probable" levels of certainty in the electrogastrographic detection of dysrhythmias.

Because there is no evidence that frequencies of <1 cpm originate from the stomach, peaks in the spectra with a frequency of <1 cpm should not be analyzed. The frequency of the gastric pacemaker with the highest frequency is normally taken over by the whole stomach.⁷ Therefore, low frequencies occurring during the presence of normal 3-cpm activity are probably not of gastric origin and should not be interpreted as such. In our opinion, the conclusion that a signal in the low-frequency range represents gastric myoelectrical activity can only be drawn when a gradual shift of the dominant gastric frequency toward a lower frequency is observed.

It is important to recognize harmonics and distinguish these from other signals in the high-frequency range because harmonics in frequency spectra result from the analysis of a nonsinusoidal signal, not from the presence of independent high frequencies in the signals. In multiple-channel EGG recordings, a signal in the high-frequency range may be seen in one channel while at the same time a normal 3-cpm signal is present in another channel. In such a case the presence of a tachygastria should be considered as probable. When, in addition to a 3-cpm peak, a peak in the high-frequency range is present, not being a secondary harmonic, it should also be labeled as probable tachygastria rather than considered definite proof of the presence of a tachygastria.

Spectra in which multiple peaks are present, in the absence of a dominant peak, may indicate movement artifacts (e.g., those caused by vomiting, retching, eating, and drinking) or be indicative of a bad recording technique (electrode noise, interference from other electrical appliances). These spectra should be discarded in the analysis. Spectra in which only peaks with a very low power are present may be the consequence of a bad recording technique or absence of normal or tachygastric myoelectrical activity. Spectra like these are best disregarded.

Most of the pitfalls discussed above can be avoided by visual inspection of the raw signals and the frequency spectra, which we believe is therefore still essential in the analysis of the EGG. The criteria used in our laboratory for the analysis of EGG frequency spectra are listed in Table 1.

Because EGG amplitude depends on the position of the gastric wall with respect to the electrodes, skin impedance, and contact of electrodes to the skin,^{5,50} absolute amplitude is a rather unreliable EGG parameter. It is likely to differ in recordings made with different sets of electrodes. At best, within-subject changes in amplitude can be compared in recordings obtained during one recording session, using the same electrodes. Because the meaning of changes in power of the EGG is incompletely understood, they should be interpreted very carefully.

Use of Computers in EGG

The use of computers has become inevitable in EGG. Computer assistance is necessary to determine frequencies in lengthy EGG recordings. However, interpretation of computer-generated data should be performed with caution. Visual inspection of the signal remains necessary to check the data generated by computer analysis. For example, movement artifacts can be easily recognized by visual inspection but will be included in the computer analysis and might be interpreted as abnormal gastric frequencies.

At present, no software is available that provides a fully automatic EGG analysis. In our opinion computers should be used only to calculate parameters that are directly related to the recorded signal. Computer software developers might be tempted to introduce new EGG

parameters, generated by complicated computer analysis. However, such new parameters should be introduced with extreme caution and their value should be proven to prevent the introduction of even more meaningless parameters in EGG analysis. Computer algorithms might also be used to detect movement artifacts in EGG signals. However, at present no validated software is available for this purpose. This might be useful especially in the analysis of ambulatory recordings. The use of algorithms for the determination of propagation of gastric electrical waves from multichannel EGG recordings is still in an experimental state.

Role of EGG in Research

When the pitfalls discussed above are taken into account, EGG is a reliable method to study gastric myoelectrical activity in a research setting. Because myoelectrical activity of the stomach underlies its motor activity, EGG provides insight in the mechanisms that play a role in the regulation of gastric motility. A major advantage of EGG is that it is a noninvasive technique that can be combined with other techniques. Many EGG studies have shown changes in gastric myoelectrical activity in response to certain stimuli such as meal ingestion,⁵¹ hyperglycemia,^{28,52} temperature,^{53,54} and intraduodenal nutrient infusion.^{52,55}

Use of EGG in Clinical Practice

EGG could be an attractive technique for clinical applications because of its noninvasiveness. Numerous reports show abnormalities in EGG in several disease states (see Koch et al.⁴ and Chen and McCallum²⁴ for review). The most frequently described abnormalities are abnormal high frequencies or tachygastrias, observed in, for example, pseudo-obstruction, gastroparesis, diabetes, nausea, functional dyspepsia, peptic ulcer disease, and postoperative states.⁴ Abnormal low frequencies or bradygastrias are also more commonly observed in these disease states. EGG may obtain a role in the work-up of patients with gastroparesis. A delayed gastric emptying time is associated with abnormalities in gastric myoelectrical activity,⁵⁶⁻⁶¹ and EGG might even distinguish gastroparesis caused by mechanical obstruction from other forms of gastroparesis.⁵⁹ The sensitivity of EGG to detect a delay in gastric emptying time is not >50% but with a specificity of 78%–92%.^{60,61}

Unfortunately, several factors limit the clinical value of EGG. Tachygastrias and bradygastrias can also be recorded to a certain extent in healthy subjects.³⁷ Therefore, not only the presence but also the percentage of time during which abnormal rhythms are presented are important in the clinical application of EGG. EGG is not a

Table 1. Definitions in the Analysis of Frequency Spectra of Cutaneous 4-Channel Recordings of Gastric Myoelectrical Activity

Normal ^a	Peak in frequency range, 2.6–3.7 cpm
Normal with harmonics	Peak in frequency range, 2.6–3.7 cpm, with 1 or more peaks at exact multiples of the fundamental frequency
Dominant low frequency	Peak in frequency range, 1.0–2.6 cpm, in the absence of a peak in the normal range
Dominant high frequency	Peak in frequency range, 3.7–10.0 cpm, in the absence of a peak in the normal range and present in all recording channels
Probable abnormal high frequency	Peak in frequency range, 3.7–10.0 cpm, not a harmonic, in the presence of a well-defined peak in the normal range or a normal signal in 1 of the other recording channels
Noise/no signal	Either no clear peak, or multiple peaks in the frequency spectrum, or strong elevation of the baseline, or significant noise or artifacts in the raw signal

NOTE. Only well-defined peaks in the spectrum are used for analysis.
^aNormal values are based on a group of 52 healthy controls.³³

substitute for a manometric study of gastric motor activity or for a scintigraphic study of gastric emptying. The EGG may even be normal in a patient with significant gastric motility disorders.⁶⁰ At present there is insufficient evidence to support a role for EGG in the clinical or diagnostic work-up of patients with gastrointestinal (or other) diseases. However, an increasing number of studies suggest that EGG may be clinically useful in the future.

Pediatric Use of EGG

Because of its noninvasive nature, EGG is potentially an attractive technique for use in children. However, especially in very young children (<4 years), EGG recordings are frequently disturbed by body movements. Rumination, vomiting, and crying in small children are associated with powerful contractions of the abdominal wall, making the recording of gastric myoelectrical activity difficult, if not impossible. Automated frequency analysis cannot be relied on under these conditions. Also, dimensions of the stomach in, for example, newborns are completely different from those of adults and may influence the cutaneously recorded signal; specially designed recording and analysis methods may be needed for different age groups.⁶² Although abnormal EGG rhythms have been described in children with various diseases,^{58,63,64} data showing that EGG is a diagnostic tool in children are not available. Especially for diagnosis of pseudo-obstruction, EGG has been shown to be less reliable than manometry and scintigraphy.⁵⁸ Similar to its use in adults, EGG can be used in clinical pediatric research, especially in older children, but presently EGG in children has not provided useful information for diagnostic purposes.

Conclusion

EGG is an important research tool to study gastric motility, providing information on the electrical activity that underlies gastric motor activity. Frequency analysis has been introduced in the realm of EGG to enable quantitative analysis of the signals. However, visual inspection of raw signals and frequency spectra remains essential in the analysis of EGG signals. Artifacts and EGG waveform changes may give rise to frequency spectra that can easily be misinterpreted. All users of EGG should be familiar with the basic principles of frequency analysis. A clinical role for EGG as a diagnostic tool in adults and children still needs to be established.

References

- Alvarez WC. The electrogastrogram and what it shows. *JAMA* 1922;78:1116-1119.
- Abell TL, Malagelada JR. Electrogastrography: current assessment and future perspectives. *Dig Dis Sci* 1988;33:982-992.
- Chen JDZ, Pan J, McCallum RW. Clinical significance of gastric myoelectrical dysrhythmias. *Dig Dis* 1995;13:275-290.
- Koch KL, Stern RM. Electrogastrography. In: Kumar D, Wingate D, eds. *An illustrated guide to gastrointestinal motility*. 2nd ed. Edinburgh: Churchill Livingstone; 1993:290-307.
- Smout AJPM, Jebbink HJA, Samsom M. Acquisition and analysis of electrogastrographic data—the dutch experience. In: Chen JZ, McCallum RW, eds. *Electrogastrography: principles and applications*. New York: Raven, 1994:3-30.
- Chen JZ, McCallum RW. Electrogastrographic parameters and their clinical significance. In: Chen JZ, McCallum RW, eds. *Electrogastrography: principles and applications*. New York: Raven, 1994:45-73.
- Hinder RA, Kelly KA. Human gastric pacesetter potential. *Am J Surg* 1977;133:29-33.
- Nelsen TS, Kohatsu S. Clinical electrogastrography and its relationship to gastric surgery. *Am J Surg* 1968;116:215-222.
- Kwong NK, Brown BH, Whittaker GE, Duthie HL. Electrical activity of the gastric antrum in man. *Br J Surg* 1970;57:913-916.
- Duthie HL, Kwong NK, Brown BH, Whittaker GE. Pacesetter potential of the human gastroduodenal junction. *Gut* 1971;12:250-256.
- Aldrete JS, Shepard RB, Halpern NB, Jimenez H, Piantadosi S. Effects of various operations on the electrical activity of the human recorded during the postoperative recovery period. *Ann Surg* 1982;195:662-669.
- Sarna SK. Gastrointestinal electrical activity: terminology. *Gastroenterology* 1975;68:1631-1635.
- Smout AJPM, Van der Schee EJ, Grashuis JL. What is measured in electrogastrography? *Dig Dis Sci* 1980;25:179-187.
- Nelsen TS, Eigenbrodt EH, Keoshian LA, Bunker C, Johnson L. Alterations in muscular and electrical activity of the stomach following vagotomy. *Arch Surg* 1967;94:821-835.
- Familoni BO, Bowes KL, Kingma YJ, Cote KR. Can transcutaneous recordings detect gastric electrical abnormalities? *Gut* 1991;32:141-146.
- Hamilton JW, Bellahsene BE, Reichelderfer M, Webster JG, Bass P. Human electrogastrograms. Comparison of surface and mucosal recordings. *Dig Dis Sci* 1986;31:33-39.
- Abell TL, Malagelada JR. Glucagon-evoked gastric dysrhythmias in humans shown by an improved electrogastrographic technique. *Gastroenterology* 1985;88:1932-1940.
- Stoddard CJ, Smallwood R, Brown BH, Duthie HL. The immediate and delayed effects of different types of vagotomy on human gastric myoelectrical activity. *Gut* 1975;16:165-170.
- You CH, Lee KY, Chey WY, Menguy R. Electrogastrographic study of patients with unexplained nausea, bloating, and vomiting. *Gastroenterology* 1980;79:311-314.
- Brown BH, Smallwood RH, Duthie HL, Stoddard CJ. Intestinal smooth muscle electrical potentials recorded from surface electrodes. *Med Biol Eng Comput* 1975;13:97-103.
- Van der Schee EJ, Grashuis JL. Running spectrum analysis as an aid in the representation and interpretation of electrogastrographic signals. *Med Biol Eng Comput* 1987;25:57-62.
- Mintchev MP, Kingma YJ, Bowes KL. Accuracy of cutaneous recordings of gastric electrical activity. *Gastroenterology* 1993;104:1273-1280.
- Smout AJPM, Van der Schee EJ. Computer analysis of cutaneously recorded gastric electrical activity. *Automedica* 1987;9:331-345.
- Chen JZ, McCallum RW. Clinical applications of electrogastrography. *Am J Gastroenterol* 1993;88:1324-1336.
- Mintchev MP, Stickel A, Bowes KL. Comparative assessment of power dynamics of gastric electrical activity. *Dig Dis Sci* 1997;42:1154-1157.
- Mintchev M, Otto SJ, Bowes KL. Electrogastrography can recog-

- nize gastric electrical uncoupling in dogs. *Gastroenterology* 1997;112:2006–2011.
27. Familoni BO, Kingma YJ, Bowes KL. Noninvasive assessment of human gastric motor function. *IEEE Trans Biomed Eng* 1987;34:30–36.
 28. Jebbink RJA, Samsom M, Bruijs PPM, Bravenboer B, Akkermans LMA, Van Berge-Henegouwen GP, Smout AJPM. Hyperglycemia induces abnormalities of gastric myoelectrical activity in patients with type I diabetes mellitus. *Gastroenterology* 1994;107:1390–1397.
 29. Clevers GJ, Smout AJPM, Van der Schee EJ, Akkermans LMA. Changes in gastric electrical activity in patients with severe post-operative nausea and vomiting. *J Gastrointest Motil* 1992;4:61–69.
 30. Mintchev M, Bowes KL. Capabilities and limitations of electrogastragrams. In: Chen JZ, McCallum RW, eds. *Electrogastrography: principles and applications*. New York: Raven, 1994:155–169.
 31. Lin Z, Chen JDZ. Comparison of three running spectrum analysis methods for electrogastrographic signals. *Med Biol Eng Comput* 1995;33:596–604.
 32. Chen J, Vandewalle J, Sansen W, Vantrappen G, Janssens J. Adaptive spectral analysis of cutaneous electrogastric signals using autoregressive moving average modelling. *Med Biol Eng Comput* 1990;28:531–536.
 33. Geldof H, Van der Schee EJ, Van Blankenstein M, Grashuis JL. Electrogastrographic study of gastric myoelectrical activity in patients with unexplained nausea and vomiting. *Gut* 1986;27:799–808.
 34. Familoni BO, Abell TL, Bowes KL. A model of gastric electrical activity in health and disease. *IEEE Trans Biomed Eng* 1995;42:647–657.
 35. Liang J, Chen JDZ. What can be measured from surface electrogastrography. *Dig Dis Sci* 1997;42:1331–1343.
 36. Geldof H, Van der Schee EJ, Grashuis JL. Electrogastrographic characteristics of interdigestive migrating complex in humans. *Am J Physiol* 1986;250:G165–G171.
 37. Pfaffenbach B, Adamek RD, Kuhn K, Wegener M. Electrogastrography in healthy subjects. Evaluation of normal values, influence of age and gender. *Dig Dis Sci* 1995;40:1445–1450.
 38. Mantides A, Stefanides G, Kioulanis J, Tzovaras G, Epanomeritakis E, Xynos E. Cutaneous electrogastrography for the assessment of gastric myoelectrical activity in type I diabetes mellitus. *Am J Gastroenterol* 1997;92:1190–1193.
 39. Kim MS, Chey WD, Owyang C, Hasler WL. Role of plasma vasopressin as a mediator of nausea and gastric slow wave dysrhythmias in motion sickness. *Am J Physiol* 1997;272:G853–G862.
 40. Homma S, Shimakage N, Yagi M, Hasegawa J, Sato K, Matsuo H, Tamiya Y, Tanaka O, Muto T, Hatakeyama K. Electrogastrography prior to and following total gastrectomy, subtotal gastrectomy, and gastric tube formation. *Dig Dis Sci* 1995;40:893–900.
 41. Koch KL, Stern RM. Electrogastrographic data acquisition and analysis—the Penn State experience. In: Chen JZ, McCallum RW, eds. *Electrogastrography: principles and applications*. New York: Raven 1994:31–44.
 42. Uijtendhaage SJH, Stern RM, Koch KL. Effects of eating on vection-induced motion sickness, cardiac vagal tone, and gastric myoelectrical activity. *Psychophysiology* 1992;29:193–201.
 43. Lindberg G, Iwarzon M, Hammarlund B. 24-Hour ambulatory electrogastrography in healthy volunteers. *Scand J Gastroenterol* 1996;31:658–664.
 44. Chen J, McCallum RW. Electrogastrography: measurement analysis and prospective applications. *Med Biol Eng Comput* 1991;29:339–350.
 45. Mintchev MP, Bowes KL. Conoidal dipole model of electrical field produced by the human stomach. *Med Biol Eng Comput* 1995;33:179–184.
 46. Mintchev M, Bowes KL. Impact of external factors on the stability of human electrogastragrams. *Med Biol Eng Comput* 1996;34:270–272.
 47. Mintchev M, Stickel A, Bowes K. Impact of different electrode surface areas on validity of human electrogastragrams. *Med Biol Eng Comput* 1997;35:66–68.
 48. Familoni BO. Validity of the cutaneous electrogastragram. In: Chen JZ, McCallum RW, eds. *Electrogastrography: principles and applications*. New York: Raven 1994:103–125.
 49. Mintchev M, Bowes KL. Extracting quantitative information from digital electrogastragrams. *Med Biol Eng Comput* 1996;34:244–248.
 50. Chen JDZ, Richards RD, McCallum RW. Identification of gastric contractions from the cutaneous electrogastragram. *Am J Gastroenterol* 1994;89:79–85.
 51. Geldof H, Van der Schee EJ, Van Blankenstein M, Smout AJPM, Akkermans LMA. Effects of highly selective vagotomy on gastric myoelectrical activity—an electrogastrographic study. *Dig Dis Sci* 1990;35:969–975.
 52. Hebbard GS, Samsom M, Andrews JM, Carman D, Tansell B, Sun WM, Dent J, Horowitz M. Hyperglycemia affects gastric electrical rhythm and nausea during intraduodenal triglyceride infusion. *Dig Dis Sci* 1997;42:568–575.
 53. Houghton LA, Read NW, Heddle R, Maddern GJ, Downton J, Touli J, Dent J. Motor activity of the gastric antrum, pylorus, and duodenum under fasted conditions and after a liquid meal. *Gastroenterology* 1988;94:1276–1284.
 54. Verhagen MAMT, Luijk HD, Samsom M, Smout AJPM. Effect of meal temperature on the frequency of gastric myoelectrical activity. *Neurogastroenterol Motil* 1998;10:175–181.
 55. Verhagen MAMT, Samsom M, Smout AJPM. Effects of intraduodenal glucose infusion on gastric myoelectrical activity and antropyloroduodenal motility. *Am J Physiol* 1998;274:G1038–G1044.
 56. Abell TL, Camilleri M, Hench VS, Malagelada JR. Gastric electromechanical function and gastric emptying in diabetic gastroparesis. *Eur J Gastroenterol Hepatol* 1991;3:163–167.
 57. Pfaffenbach B, Adamek RJ, Bartholomaeus C, Wegener M. Gastric dysrhythmias and delayed gastric emptying in patients with functional dyspepsia. *Dig Dis Sci* 1997;42:2094–2099.
 58. Di Lorenzo C, Reddy SN, Flores AF, Hyman PE. Is electrogastrography a substitute for manometric studies in children with functional gastrointestinal disorders? *Dig Dis Sci* 1997;42:2310–2316.
 59. Brzana RJ, Koch KL, Bingaman S. Gastric myoelectrical activity in patients with gastric outlet obstruction and idiopathic gastroparesis. *Am J Gastroenterol* 1998;93:1803–1809.
 60. Chen JDZ, Lin Z, Pan J, McCallum RW. Abnormal gastric myoelectrical activity and delayed gastric emptying in patients with symptoms suggestive of gastroparesis. *Dig Dis Sci* 1996;41:1538–1545.
 61. Parkman HP, Miller MA, Trate D, Knight LC, Urbain JL, Maurer AH, Fisher RS. Electrogastrography and gastric emptying scintigraphy are complementary for assessment of dyspepsia. *J Clin Gastroenterol* 1997;24:214–219.
 62. Mintchev MP, Bowes KL. Computer simulation of the impact of different dimensions of the stomach on the validity of electrogastragrams. *Med Biol Eng Comput* 1998;36:7–10.
 63. Cucchiara S, Franzese A, Salvia G, Alfonsi L, Iula VD, Montisci A, Moreira FL. Gastric emptying delay and gastric electrical derangement in IDDM. *Diabetes Care* 1998;21:438–443.
 64. Riezzo G, Cucchiara S, Chiloiro M, Minella R, Guerra V, Giorgio I. Gastric emptying and myoelectrical activity in children with nonulcer dyspepsia. Effect of cisapride. *Dig Dis Sci* 1995;40:1428–1434.

Received January 30, 1998. Accepted April 19, 1999.

Address requests for reprints to: Marc A. M. T. Verhagen, M.D., Department of Gastroenterology, University Hospital Utrecht, P.O. Box 85500, 3508 GA Utrecht, The Netherlands. fax: (31) 30-2507371.