

CASE REPORTS

Evolution of Acute Cytomegalovirus Gastritis to Chronic Gastrointestinal Dysmotility in a Nonimmunocompromised Adult

THOMAS V. NOWAK, MATTHEW GODDARD, BYRON BATTEIGER, and O. WILLIAM CUMMINGS

Research Department, St. Vincent Hospital, and Departments of Medicine and Pathology, Indiana University School of Medicine, Indianapolis, Indiana

A 30-year-old nonimmunocompromised woman developed chronic gastrointestinal dysmotility as a consequence of acute cytomegalovirus infection. The acute nature of the infection was documented by high immunoglobulin M antibody titer to cytomegalovirus (CMV); the chronicity of the infection was shown by persistence of CMV in biopsy specimens of her gastrointestinal tract over a 2½-year period. Gastrointestinal dysmotility was confirmed by delayed emptying on gastric nuclear scintigraphy, by retrograde propagation of migrating myoelectric complexes on small intestinal manometry, and by presence of tachygastric on cutaneous electrogastrigraphy. The patient's nausea, vomiting, abdominal pain, and early satiety resolved after a short course of treatment with leuprolide acetate but returned after medication was discontinued. Her symptoms persisted despite clearance of CMV from the gastrointestinal tract after a course of treatment with ganciclovir. These observations show that acute CMV infection can cause gastrointestinal dysmotility in nonimmunocompromised individuals and that the disturbance in gastrointestinal motor function may persist for years after viral infection of the gastrointestinal tract has been eradicated.

Delayed gastric emptying as a consequence of acute viral gastroenteritis has been recognized for nearly three decades.¹ A growing number of viruses have been implicated including herpes zoster,² Epstein-Barr virus,^{3,4} cytomegalovirus (CMV),^{5,6} rotaviruses,⁷ and Norwalk and Hawaii viruses.⁸ In most instances, the delay in gastric emptying is transient and returns to normal after the patient recovers from the viral infection.^{7,8}

Although viral infection is suspected as the cause of chronic gastroparesis and intestinal dysmotility in some patients who present with an acute onset of nausea and vomiting, such an association is not substantiated in the medical literature and is difficult to prove in a clinical setting. An acute attack of nausea, vomiting, and abdominal distention is usually viewed as a self-limited viral

illness, and extensive and expensive diagnostic studies into the viral etiology of the illness are not pursued. When the symptoms become chronic, months to years later, the patient may no longer shed the virus, and its recognition by culture or histological methods may be impossible. This case report describes a patient who developed chronic gastrointestinal dysmotility as a consequence of acute CMV-induced gastroenteritis. The pathophysiological effect of the virus was documented by the development of delayed gastric emptying, by production of tachygastric, and by abnormal propagation of migrating myoelectrical complexes in the small intestine.

Case Report

A 30-year-old female greenhouse manager was hospitalized at Indiana University Medical Center in March 1992 for nausea, vomiting, and abdominal pain. She was in good health until Christmas of 1991, when she noted the onset of an upper respiratory tract infection. One week later, she noted nausea, vomiting, and abdominal pain. Her upper respiratory tract symptoms resolved but her nausea and vomiting continued, and she was hospitalized twice at a community hospital. Ultrasonography of the gallbladder, computerized tomography scans of the abdomen and head, hepatobiliary scan, upper gastrointestinal endoscopy, and air-contrast barium enema examination showed no abnormalities. Laboratory evaluation showed an immunoglobulin (Ig) M level of 1270 mg/dL (normal, 650-1600), IgA level of 135 mg/dL (normal, 60-350), and IgM level of 331 mg/dL (normal, 50-300). An enteroclysis study showed mucosal thickening in the jejunum. An exploratory laparotomy was performed, and no anatomic abnormalities were noted. A feeding jejunostomy tube was placed, and a full-thickness intestinal biopsy specimen was obtained, which was normal on histological examination.

On transfer to Indiana University Medical Center, the patient's vital signs were normal. A head and neck examination showed no adenopathy. The lungs were clear, and cardiac

Abbreviation used in this paper: CMV, cytomegalovirus.

© 1999 by the American Gastroenterological Association
0016-5085/99/\$10.00

examination showed no murmurs. There were hypoactive bowel sounds on abdominal examination, but no tenderness. The liver was not enlarged, and there was no splenomegaly. Rectal examination showed no abnormalities.

Review of the patient's medical history showed that she had been in good health, except for one episode of facial herpes zoster 2 years earlier. The laboratory evaluation was consistent with an acute viral infection. The serum alanine aminotransferase level was 139 IU/L (normal, 0–35); aspartate aminotransferase 76 IU/L (normal, 25–45); and γ -glutamyl transpeptidase 99 IU/L (normal, 5–55). White blood cell count was 6800, with 47% lymphocytes, 2 monocytes, and 4 eosinophils. A qualitative mononucleosis antibody was negative. Epstein-Barr virus IgM serology titer was 1:10, and IgG titer was 1:640. The CMV IgM titer was 1:80, and CMV IgG enzyme immunoassay quantitative index was 3.00. A nuclear gastric emptying scintiscan, using radio-labeled egg whites, showed delayed gastric emptying with 63% retention at 60 minutes (normal, 21%–45%) and 29% retention at 90 minutes (normal, 8%–28%). An upper gastrointestinal endoscopy showed mild prepyloric edema. Biopsy specimens of the antrum showed chronic inflammation, and no *Helicobacter pylori* was visualized. Cultures of the antral biopsy specimens grew CMV (Table 1). A small intestinal manometry (April 1992) was performed by placing an eight-lumen multiport perfusion catheter near the ligament of Treitz under fluoroscopic control. The patient was placed in the supine position, and the recording was continued for 4–6 hours in the fasted state and for 1–2 hours after oral ingestion of a test meal consisting of one carton of Resource Plus (Sandoz Pharmaceuticals, East Hanover, NJ). The manometry study showed no abnormalities, with normal aboral propagation of migrating myoelectric complexes during fasting (Figure 1). Cutaneous electrogastrography was performed by placing four bipolar recording and one

ground electrode on the upper abdomen in a line parallel to the longitudinal axis of the stomach (Sandhill Scientific, Littleton, CO). Gastric myoelectrical activity was recorded continuously for 60 minutes in the baseline state and for an additional 60 minutes after ingestion of a light meal consisting of one cup of instant soup. Preprandial and postprandial recordings were digitized at 4.27 Hz, and the signal was subjected to autoregressive spectral analysis. The electrogastrogram was abnormal and

Table 1. Results of Viral Culture for CMV From Blood or Endoscopically Obtained Biopsy Specimens

| Date | Site | Result |
|----------|-----------------------------------|--------|
| 3/28/92 | Blood | — |
| 3/30/92 | Stomach | + |
| 5/29/92 | Stomach | + |
| 11/19/92 | Stomach | + |
| 11/19/92 | Stomach | — |
| 2/25/93 | Stomach | + |
| 2/25/93 | Blood | — |
| 3/3/93 | Stomach | — |
| 3/18/93 | Small intestine | — |
| 12/13/93 | Stomach | — |
| 12/15/93 | Colon | + |
| 12/21/93 | Blood | — |
| 12/93 | Intravenous ganciclovir treatment | — |
| 12/93 | Intravenous ganciclovir treatment | — |
| 1/13/94 | Colon | — |
| 7/29/94 | Rectum | — |
| 8/2/94 | Stomach | — |
| 11/17/94 | Cecum | — |
| 12/12/95 | Colon | — |

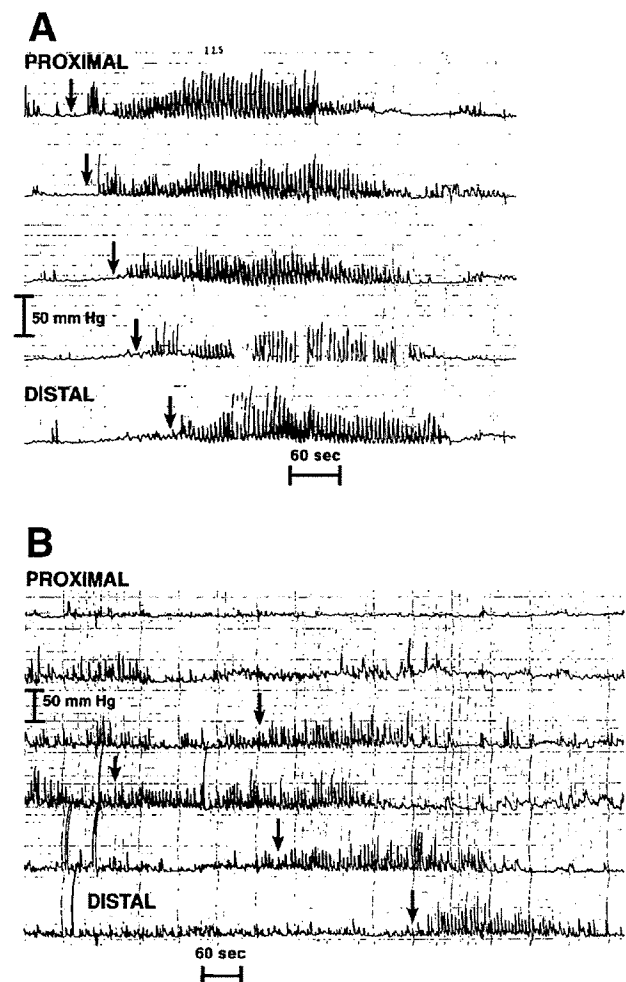


Figure 1. (A) Small intestinal manometry performed approximately 3 months after the patient presented with nausea, vomiting, and abdominal pain. Five recording channels are shown. Note the normal orderly progression of the migrating myoelectrical complexes from proximal to distal recording sites. The onset of the complex in each recording channel is shown by arrows. The remainder of the fasting pattern, as well as the postprandial recording, was normal. (B) Small intestinal manometry performed 15 months after the onset of the patient's illness. Six recording channels are shown. Each arrow designates the onset of a migrating myoelectrical complex. Note the disorganized propagation of the complex. The complex shows a premature onset in the fourth recording channel. From this point, the complex shows an abnormal retrograde propagation into channel 3 but no further propagation into channels 2 and 1. The distal aboral propagation of the complex from channels 4–6 is normal. No complex is recorded in either channel 1 or 2.

showed replacement of the normal gastric myoelectrical rhythm of 3 cycles per minute (cpm) by an accelerated 5–9-cpm rhythm, i.e., tachygastria (Figure 2). The patient's symptoms improved spontaneously. She was able to eat some solid food and was discharged from the hospital.

Several weeks later, the patient's emeses returned, and she was treated with an erythromycin suspension, 200 mg orally four times daily. Upper gastrointestinal endoscopy (May 1992) showed no abnormalities. Endoscopic biopsy specimens of the antrum and small intestine were normal on histological examination, but cultures of the antral biopsies grew CMV. A CMV serology titer (IgM) was 1:10. A gastric emptying scintiscan (June 1992) was attempted but could not be performed because the patient vomited. A human immunodeficiency virus titer was nonreactive. Jejunostomy tube feedings were resumed. Over the next 3 months, the patient was also treated with bethanechol and promethazine, neither of which were satisfactorily able to control her vomiting.

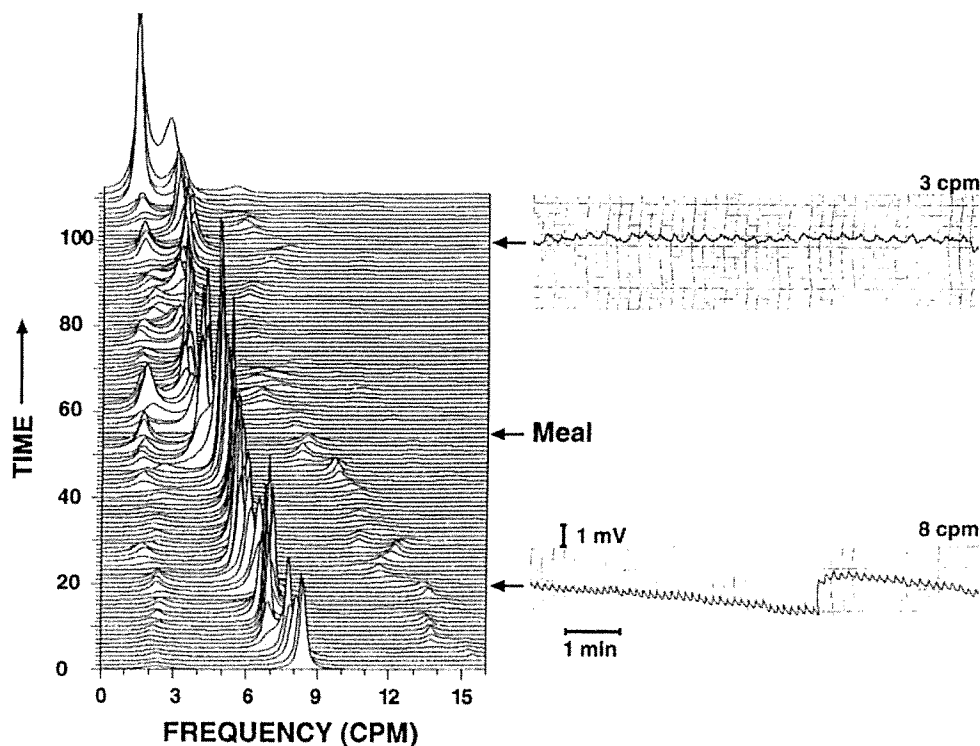
Eight months after the onset of her illness (August 1992), treatment with leuprolide, 0.5 mg subcutaneously every day, was initiated. Within 2 weeks after initiating treatment, the patient noted an improvement in her nausea and a diminution in her vomiting. Her appetite improved, and she was able to eat all food items, except ice cream. Within 1 month of starting leuprolide treatment, her menses stopped and she began experiencing hot flashes. Estrogen supplementation was initiated. An upper gastrointestinal endoscopy (November 1992) showed mild erosive antritis and duodenal erythema. Biopsy specimens of the antrum and small intestine showed mild, chronic inflammation of the antrum and intestinal metaplasia.

CMV was isolated from cultures of the antral biopsy specimens. The patient was eating with minimal vomiting, and at her request the jejunostomy feeding tube was removed. Because of her concern over the medication's potential side effects, leuprolide treatment was discontinued after 3 months of treatment (December 1992). She was able to enjoy her Thanksgiving and Christmas meal celebrations with no nausea or vomiting.

Approximately 2 months after discontinuing leuprolide treatment (January 1993), her menses returned and 1 month later (February 1993) her nausea and vomiting resumed. Fourteen months after the original onset of her illness, she was hospitalized for dehydration caused by vomiting. A gastric emptying scintiscan was unsuccessful because the patient vomited the test meal. Upper gastrointestinal endoscopy showed mild erosive antritis. Specimens of the antrum taken for viral culture grew CMV. An enteroclysis study showed normal findings. The patient underwent an exploratory laparotomy with adhesiolysis, full-thickness biopsy of the small intestine, and construction of a surgical jejunostomy feeding tube. Histological examination of the full-thickness intestinal biopsy sample showed no abnormalities. Cultures of the intestinal biopsy were likewise normal. A small intestinal manometry (March 1993) showed abnormalities in the migrating myoelectrical complexes that included retrograde propagation (Figure 1), failure of propagation of the complex, simultaneous onset in several recording channels, or unusually low-amplitude contractions. Treatment with leuprolide acetate, 1 mg per day subcutaneously, was initiated.

Seventeen months after the onset of her illness, the patient

Figure 2. Cutaneous electrogastrography performed during the patient's initial hospitalization. Representative preprandial and postprandial analog recordings are shown on the right. The autoregressive analysis of the analog signal is shown on the left. The preprandial analog recording (lower right) shows an accelerated gastric myoelectrical rhythm (tachygastria) of 8 cpm. The postprandial analog recording (upper right) shows a rhythm of 3 cpm. The autoregressive analysis (left) of the entire recording shows that the accelerated gastric rhythm of 8 cpm gradually slows down and that, after the test meal has been consumed, a predominant gastric rhythm of 3–4 cpm is recorded.



was hospitalized (May 1993) at another institution for nausea, vomiting, and abdominal pain. Antral biopsy and small intestinal biopsy specimens obtained during an upper gastrointestinal endoscopy showed no growth of CMV. A gastric emptying scintiscan showed delayed gastric emptying with 50% activity remaining in the stomach after 2 hours (normal, 53%–76%) and 54% after 4 hours (normal, 0%–44%). Leuprolide treatment was discontinued, and the patient was maintained on jejunostomy tube feedings. Treatment with both cisapride and misoprostol was administered, with no appreciable relief of her symptoms.

Nearly 2 years after the onset of her illness, she was hospitalized with abdominal pain (December 1993). A colonoscopy showed a normal terminal ileum and normal right and transverse colons. Multiple ulcers, ranging in size from 2 to 15 mm, were noted in the sigmoid colon and proximal rectum. Biopsy specimens showed mild nonspecific inflammation on histological examinations. No viral inclusions were seen. Cultures of the colonic biopsies grew CMV. The patient underwent a 20-day course of intravenous ganciclovir, with partial relief of her abdominal pain. One month later, flexible fiberoptic sigmoidoscopy showed no abnormalities. No histological changes were noted in the sigmoidoscopic biopsy specimens, and the viral cultures of the sigmoidoscopic specimens showed no growth.

Nearly 32 months after the onset of her illness (July 1994), the patient continued to vomit. Treatment with domperidone was initiated but discontinued after 3 weeks because of headaches. An upper gastrointestinal endoscopy and colonoscopy showed normal findings. Because of continued abdominal pain and vomiting, a Hickman catheter was placed and total parenteral nutrition was initiated. Over the subsequent 3 months, the patient was hospitalized three times because of bacteremia and sepsis. After the third bout of sepsis, total parenteral nutrition was discontinued and the Hickman catheter removed. A colonoscopy performed 35 months after the onset of her illness (November 1994) was normal, and colonoscopic biopsy specimens showed no CMV on culture. Treatment with leuprolide, 0.5 mg/day subcutaneously, was initiated. Over the next several months the dose was gradually increased to a dose of 1 mg/day. One year later (December 1995), the patient complained of rectal bleeding. A colonoscopy showed no abnormalities. Colonoscopic biopsy specimens were normal on histological examination, and cultures of colonoscopic specimens were negative for any viruses.

The patient's nausea continues to the present day, more than 6 years after onset of her illness. She is unable to eat either solid or liquid food without vomiting. She vents her gastrostomy tube several times per day to obtain relief from gastric retention. Nutrition is maintained by constant infusion of an elemental diet through a surgically placed jejunostomy tube. She is being treated with leuprolide, oxycodone, acetaminophen, promethazine, and meperidine, and she is currently awaiting surgical placement of an artificial gastric pacemaker.

Discussion

The present case is unique in that it describes a previously healthy woman in whom chronic gastrointestinal dysmotility developed as a consequence of an acute CMV infection. The acute nature of the infection was documented by the positive IgM serology for CMV (1:80 titer). The chronicity of the infection was evidenced by the culture of CMV from endoscopically obtained antral biopsy specimens on several occasions and from specimens of colonic ulcers nearly 25 months after the onset of her illness. After treatment of the CMV infection with a course of intravenous ganciclovir, the colonic ulcers resolved and gastric and colonic biopsy specimens no longer grew CMV on culture, although the patient's symptoms continued.

Disordered gastrointestinal motility was documented by the consistent delay in gastric emptying shown on gastric emptying scintiscan for the initial 17 months after the onset of her illness. At times the patient's nausea and vomiting were so severe that she could not even tolerate the ingestion of the test meal without vomiting. Cutaneous electrogastrography showed that an accelerated gastric rhythm (tachygastria) of 6–8 cpm had replaced the normal 3-cpm electrical rhythm of the stomach. Tachygastrias have been shown to be associated with nausea and vomiting in human subjects,⁹ and it is likely that the infecting CMV altered gastric emptying and produced nausea and vomiting by altering the intrinsic myoelectrical rhythm of the stomach. Finally, the patient initially showed no evidence of dysmotility involving the small intestine at the onset of her illness. She was initially able to tolerate jejunostomy tube feedings without vomiting. A small intestinal manometry 5 months after the onset of her illness showed normal aboral propagation of the migrating myoelectrical complexes. Another small intestinal manometry was performed nearly a year later when total parenteral nutrition was begun because of the patient's inability to tolerate her jejunostomy tube feedings. This study showed disordered small intestinal motility with retrograde propagation of the migrating myoelectrical complexes.

Unlike the index case who had an elevated IgM titer antibody to CMV, serological studies of patients with suspected postviral gastrointestinal dysmotility are of limited value and may simply show evidence of previous exposure to the agent. In a retrospective study of 103 patients with gastroparesis, evidence of a presumed viral illness could only be identified in 7 individuals.¹⁰ Autonomic neuropathy was found in all the 3 patients who underwent studies of autonomic function.¹⁰ This

observation lends credence to the notion that an autonomic neuropathy might be responsible for postviral gastroparesis. Such autonomic dysfunction and gastrointestinal dysmotility involving the stomach, small intestine, and colon has been described in patients as a consequence of infectious mononucleosis (Epstein-Barr virus infection).^{3,4} Sonsino et al.¹¹ described a 2-month-old male infant in whom intestinal pseudo-obstruction developed as a consequence of acute CMV infection. The diagnosis was confirmed by the demonstration of CMV-specific intranuclear inclusions in the myenteric plexus neurons in tissue obtained from a rectal biopsy.

CMV infection generally presents as a mononucleosis-like syndrome in healthy adults. Serious and life-threatening infections of the gastrointestinal tract typically occur in patients who are immunocompromised. However, invasive and ulcerative disease of the gastrointestinal tract caused by CMV has been reported in healthy adults. Many reports show that CMV infection can produce ulceration in the esophagus,¹² stomach,^{13,14} small intestine,¹⁵⁻¹⁷ and colon¹⁸⁻²² in nonimmunocompromised individuals. However, chronic gastrointestinal dysmotility as a consequence of an acute CMV infection in a nonimmunocompromised patient has not been reported.

The diagnosis of gastrointestinal CMV infection in our patient was based on the isolation of the virus from mucosal biopsy specimens from the stomach and colon, but no histopathologic changes indicative of CMV infection were found on microscopic examination. The "classic" changes of CMV infection consist of cytomegaly, intranuclear Cowdry A type inclusions, and intracytoplasmic inclusions.²³ In reality, classic inclusions are rarely found in mucosal biopsy specimens from the gastrointestinal tract.²³ In an autopsy study of 502 unselected patients, viral culture was six times more sensitive than histological examination in determining the presence of CMV infection.^{24,25} This observation is similar to one in a previously reported case of colonic CMV infection.¹⁹

The present patient initially achieved a beneficial therapeutic response to treatment with leuprolide acetate, a compound that has some value in the management of patients with refractory nausea, vomiting, and abdominal pain.²⁶ A similar case and therapeutic response to leuprolide acetate was reported by Mathias et al.,⁵ who described an adolescent female subject who developed chronic gastrointestinal pseudo-obstruction as a consequence of an acute CMV infection.⁵ These observations suggest that the use of leuprolide acetate in the treatment of patients with disordered gastrointestinal motility requires further scrutiny and investigation.

References

- Rhodes JB, Robinson RG, McBride N. Sudden onset of slow gastric emptying of food. *Gastroenterology* 1979;77:569-571.
- Kebede D, Barthel JS, Singh A. Transient gastroparesis associated with cutaneous herpes zoster. *Dig Dis Sci* 1987;32:318-322.
- Yahr MD, Frontera AT. Acute autonomic neuropathy. Its occurrence in infectious mononucleosis. *Arch Neurol* 1975;32:132-133.
- Vassallo M, Camilleri M, Caron BL, Low PA. Gastrointestinal motor dysfunction in acquired selective cholinergic dysautonomia associated with infectious mononucleosis. *Gastroenterology* 1991;100:252-258.
- Mathias JR, Baskin GS, Reeves-Darby VG, Clench MH, Smith LL, Calhoun JH. Chronic intestinal pseudoobstruction in a patient with heart-lung transplant. Therapeutic effect of leuprolide acetate. *Dig Dis Sci* 1992;37:1761-1768.
- Van Thiel DH, Gavaler JS, Schade RR, Chien M-C, Starzl TC. Cytomegalovirus infection and gastric emptying. *Transplantation* 1992;54:70-73.
- Bardhan PK, Salam MA, Molla AM. Gastric emptying of liquid in children suffering from acute rotaviral gastroenteritis. *Gut* 1992;33:26-29.
- Meeroff JC, Schreiber DS, Trier JS, Blacklow NR. Abnormal gastric motor function in viral gastroenteritis. *Ann Intern Med* 1980;92:370-373.
- Koch KL. Stomach. In: Schuster MM, ed. *Atlas of gastrointestinal motility in health and disease*. Baltimore: Williams & Wilkins, 1993:158-176.
- Oh JJ, Kim CH. Gastroparesis after a presumed viral illness: Clinical and laboratory features and natural history. *Mayo Clin Proc* 1990;65:636-642.
- Sonsino E, Mouy R, Foucaud P, Cezard JP, Aigrain Y, Bocquet L, Navarro J. Intestinal pseudoobstruction related to cytomegalovirus infection of myenteric plexus. *N Engl J Med* 1984;311:196-197.
- Villar LA, Massanri RM, Mitros FA. Cytomegalovirus infection with acute erosive esophagitis. *Am J Med* 1984;76:924-927.
- Andrade JD, Bambirra EA, Lima GF, Moreira EF, De Oliveira CA. Gastric cytomegalic inclusion bodies diagnosed by histologic examination of endoscopic biopsies in patients with gastric ulcer. *Am J Clin Pathol* 1983;79:493-496.
- Arnar DO, Gudmundsson G, Theodors A, Valtysson G, Sigfusson A, Jonasson JG. Primary cytomegalovirus infection and gastric ulcers in normal host. *Dig Dis Sci* 1991;36:108-111.
- Dent DM, Duys PJ, Bird AR, Birkenstock WE. Cytomegalic virus infection of bowel in adults. *S Afr Med J* 1975;49:669-672.
- Tajima T. An autopsy case of primary cytomegalic inclusion enteritis with remarkable hypoproteinemia. *Acta Pathol Jpn* 1974;24:151-162.
- Underwood JCE, Corbett CL. Persistent diarrhoea and hypoalbuminaemia associated with cytomegalovirus enteritis. *Br Med J* 1978;22:1029-1030.
- Blair SD, Forbes A, Parkins RA. CMV colitis in an immunocompetent adult. *J R Soc Med* 1992;85:238-239.
- Cunningham M, Cantoni L, Humair L. Cytomegalovirus primo-infection in a patient with idiopathic proctitis. *Am J Gastroenterol* 1986;81:586-588.
- Maignan M, Wahl D, Thiaucourt D, Bach D, De Korwin J-D, Vaillant G, Paille F, Schmitt J. Self-limited primary cytomegalovirus colitis in an immunocompetent individual. *J Intern Med* 1992;232:357-359.
- Surawicz CM, Myerson D. Self-limited cytomegalovirus colitis in immunocompetent individuals. *Gastroenterology* 1988;94:194-199.

22. Wolfe BM, Cherry JD. Hemorrhage from cecal ulcers of cytomegalovirus infection. Report of a case. *Ann Surg* 1973;177:490-494.
23. Schwartz DA, Wilcox CM. Atypical cytomegalovirus inclusions in gastrointestinal biopsy specimens from patients with the acquired immunodeficiency syndrome: diagnostic role of in situ nucleic acid hybridization. *Hum Pathol* 1992;23:1019-1026.
24. Smith TF, Holley KE, Keys TF, Macasaet FF. Cytomegalovirus studies of autopsy tissue. I. Virus isolation. *Am J Clin Pathol* 1975;63:854-858.
25. Macasaet FF, Holley KE, Smith TF, Keys TF. Cytomegalovirus studies of autopsy tissue. II. Incidence of inclusion bodies and related pathologic data. *Am J Clin Pathol* 1975;63:859-865.
26. Mathias JR, Ferguson KL, Clench MH. Debilitating "functional" bowel disease controlled by leuprolide acetate, gonadotropin-releasing hormone (GnRH) analog. *Dig Dis Sci* 1989;34:761-766.

Received January 5, 1998. Received December 15, 1998.

Address requests for reprints to: Thomas V. Nowak, M.D., Research Department, St. Vincent Hospital, Suite 208, 8402 Harcourt Road, Indianapolis, Indiana 46260. Fax: (765) 868-9828.

Supported by National Institutes of Health grant R01 DK43766.