

Gastric Emptying and Gastric Myoelectrical Activity in Patients with Diabetic Gastroparesis: Effect of Long-Term Domperidone Treatment

Kenneth L. Koch, M.D., Robert M. Stern, Ph.D., William R. Stewart, Ph.D.,* and Michael W. Vasey, M.S.

Departments of Medicine and Psychology, The Pennsylvania State University, Hershey and University Park, Pennsylvania

We measured gastric emptying and gastric myoelectrical activity with solid-phase gastric-emptying tests and cutaneously recorded electrogastrograms (EGGs), respectively, in six insulin-dependent diabetic patients with nausea and vomiting who did not respond to standard treatments. Baseline solid phase gastric emptying was markedly delayed ($78 \pm 8\%$ retained at 120 min) and EGG recordings revealed gastric dysrhythmias; tachygastria (4–9 cpm signals) in one patient, 1- to 2-cpm waves in two patients, and flatline patterns in three patients. No patient had a normal 3-cpm EGG pattern. After 6 months of domperidone treatment, mean upper gastrointestinal symptoms scores decreased from 17.8 to 3.7 ($p < 0.01$), and normal 3-cpm EGG frequencies were recorded from each of the six patients. The mean percentage of meal retained at 120 min decreased but did not improve significantly. Thus, establishment of normal 3-cpm gastric myoelectrical activity and resolution of dysrhythmias, not normalization of emptying rates, was associated with improvement in upper gastrointestinal symptoms in these diabetic patients.

INTRODUCTION

Early satiety, bloating, upper abdominal distention, nausea, and vomiting are upper gastrointestinal (GI) symptoms associated with gastric atony and delayed emptying of barium or isotope-labeled meals from the stomach (1–9). In the absence of other explanations, such as mechanical obstruction, upper gastrointestinal (GI) symptoms are often attributed to gastroparesis in patients with long-standing insulin-dependent diabetes mellitus. Although upper GI symptoms are often significantly diminished by gastroprokinetic drugs, the improvement in the rate of liquid and solid gastric emptying as measured by scintigraphic methods is variable (4–9). No correlation between gastric emptying rates and upper GI symptoms in diabetic patients was found in recent studies (6, 8). Thus, the relationship of

emptying rates *per se* to upper GI symptoms remains unclear.

Another physiologic event which is relevant to gastric motility is gastric slow-wave activity. Gastric contractions are coordinated normally by slow waves that migrate distally through the body and antrum at 3 cycles per minute (cpm) in man (10, 11). Abnormal slow-wave frequencies termed tachygastrias and bradygastrias have been recorded in patients with idiopathic nausea and vomiting (12, 13). Tachygastrias also have been detected in *in vitro* studies of gastric smooth muscle from a patient with severe nausea, vomiting, and gastroparesis (14). Thus, gastric dysrhythmias may be related to nausea symptoms and to delays in gastric-emptying rates.

Gastric dysrhythmias and normal 3-cpm slow-wave activity are recorded accurately by mucosal, serosal, or cutaneous electrodes (15–20). Gastric dysrhythmias have been reported in patients with dyspepsia, nausea of pregnancy, anorexia nervosa, and diabetes mellitus (21–24), and in healthy subjects after infusions of glucagon and during vection-induced motion sickness (19, 25, 26).

The aims of the present study were to obtain prospectively two measures of gastric motor activity in diabetic patients with severe nausea and vomiting: gastric myoelectrical activity, by means of electrogastrographic methods, and solid-phase gastric emptying by means of scintigraphic methods. We also wished to determine the effect of long-term domperidone therapy on upper GI symptoms, electrogastrogram (EGG) patterns, and gastric emptying.

METHODS

Patients

Six patients with insulin-dependent diabetes mellitus and severe upper GI symptoms refractory to available medical therapy were evaluated at the University Hospital, The Milton S. Hershey Medical Center, for treatment with domperidone (Janssen Pharmaceutica, Piscataway, NJ). Domperidone was administered, 20 mg

* Dr. Stewart's present address is Gastroenterology Division, University of Virginia, Charlottesville, VA.

Received Feb. 1, 1989; revised Mar. 20, 1989; accepted May 9, 1989.

by mouth four times a day, in an open-label trial. All patients were treated with domperidone for at least 6 months. Gastric emptying tests and EGGs were obtained prospectively, and the patients were unaware of their EGG or gastric-emptying results when they reported their symptom status.

Clinical characteristics of the patients were summarized in Table 1. The patients were three men and three women, ages 22–65 yr. Duration of insulin-dependent diabetes was 7–25 yr. Five of the six patients had documented retinopathy, neuropathy, or nephropathy. In one patient (TH), gastropathy was the only diabetic complication. Duration of nausea, vomiting, bloating, early satiety, and other upper GI symptoms ranged from 3 months to 7 yr. At the time of the patients' transfer to University Hospital, nausea and vomiting were the predominant symptoms, were present pre- and post-prandially, and had been refractory to bowel rest, nasogastric suction, and a variety of standard drug therapies such as prochlorperazine, trimethobenzamide, chlorpromazine, and metoclopramide. Barium and/or endoscopy studies excluded mechanical obstruction of the gastrointestinal tract in each case.

Upper GI symptom scores

The patients' symptoms were scored by rating the following: heartburn, regurgitation, eructation, anorexia, early satiety, abdominal distention, burning discomfort, flatulence, vague upper abdominal discomfort, nausea, and vomiting. Zero, one, two, or three points were assigned if the symptom was judged by the patient to be not present, mild, moderate, or severe, respectively. The major symptoms in each patient were nausea and vomiting. Total possible symptom score was 33 points.

Electrogastrography

Three standard Ag-AgCl electrodes (12.5 mm in diameter microelectrodes, SensorMedics, Anaheim CA) were positioned on the abdominal surface over the region of the stomach (E1, E2, E3), as shown in Figure 1. The fourth electrode (E4) was the common reference

electrode, and was placed in the right upper quadrant area along the line formed by E1, E2, and E3. The skin was abraded gently prior to placing the electrodes to reduce skin resistance.

The electrodes were connected to a rectilinear recorder (Beckman R612, SensorMedics) through direct nystagmus couplers (no. 9859, SensorMedics). The time constant was 10.0 s and the high frequency cutoff was 0.3 Hz. Amplification of the EGG signal was adjusted as required with preamplifier settings. The EGG signal from the rectilinear recorder was recorded on chart paper and simultaneously stored on magnetic tape (Honeywell 101, Honeywell Instruments, Denver, CO) for computer analysis.

Respiratory rate was recorded by a belt pneumograph. Patients sat in a comfortable chair for all EGG studies. EGGs and solid-phase gastric emptying studies were performed separately after an overnight fast, and domperidone was stopped 12 h before the repeat EGG and emptying tests.

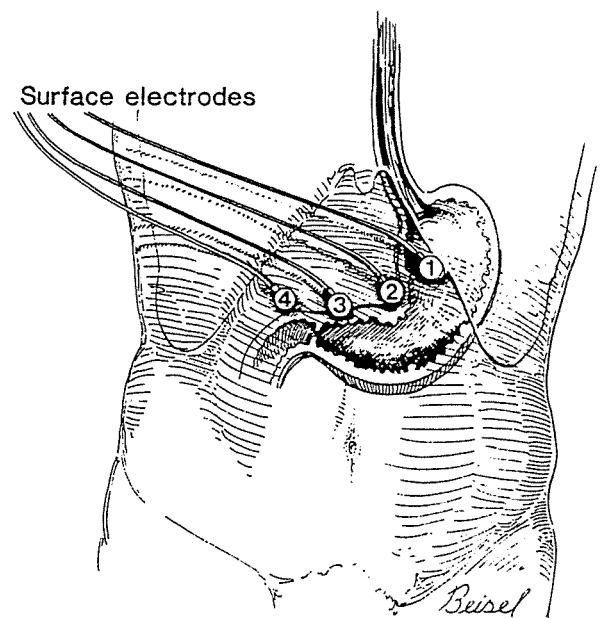


FIG. 1. Placement of the electrodes used for recording electrogastragrams. Electrode 4 is the common or reference electrode.

TABLE 1
Clinical Characteristics of Patients with Diabetic Gastroparesis

Patient	Age (yr)/Sex	Duration* (yr)	Complications	Major GI Sx	DurUGI Sx(yr)	UGI x-ray	Endos
A	53/F	25	R,NR	N,V,D	2	Normal	Normal
B	53/M	23	R,NR	N,V	1	Del emp	Normal
C	65/M	25	NR	N,V	1	Del emp	Normal
D	30/F	16	NE,R,NR	N,V	7	ND	Normal
E	22/F	7	None	N,V	0.3	Normal	RF
F	52/M	12	N,R,NR	N,V	3	ND	Normal

* Duration of diabetes; Sx, symptoms; DurUGI, duration of upper GI symptoms; Endos, upper endoscopy; R, retinopathy; NR, neuropathy; N, nausea; V, vomiting; D, distention; Del emp, delayed emptying of barium; NE, nephropathy; ND, not done; RF, retained food.

Analysis of the EGG signal

The EGG frequency was determined by visual inspection of a 30-min recording of the raw signal and computer analysis. A 3-cpm frequency was considered normal; 4- to 9-cpm frequencies were considered tachygastrias, and flatline patterns (no cyclical signal), and 1- to 2-cpm waves were considered abnormal myoelectric rhythms. EGG recordings from baseline and after 6 months of domperidone were analyzed for the study. Details of the methods used in the computer analyses are presented in the Appendix.

Solid-phase gastric emptying studies

Patients were fasted for at least 8 h before the baseline gastric emptying studies. The standard meal consisted of two eggs mixed thoroughly with 500 μ Ci of technetium-99m sulfur colloid and then cooked until done. The eggs were ingested in 3-5 min, after which the subject was given 30 ml of water to drink.

A large field-of-view camera with a parallel hole collimator was used in these studies. The energy range for ^{99m}Tc was preset with a 20% window, and the preset stop was set for 60 s. Immediately after the eggs were ingested, a static scintigraphic image was taken in the anterior position and recorded on an alpha-microdot computer. The patient relaxed in an upright position until 15 min later, when the next 1-min scintigram was obtained in the supine position. This procedure continued with 1-min scans at 15, 30, 45, 60, 75, 90, 105, and 120 min after ingestion of the eggs.

The emptying curve was established by plotting the percentage of the total meal remaining within the stomach against time, after the method described by Horowitz *et al.* (7). A region of interest was drawn around the stomach, as depicted on the computer display of counts at each time point. In each patients, the value for 100% retention of the meal was derived from the maximum gastric count obtained in the first 45 min after the meal. In studies from 10 healthy controls, the $T_{1/2}$ averaged 71 min and the percentage retained at 120 min averaged 17%. Patients with prolonged $T_{1/2}$ or percentage retained

greater than 2 SD above the mean at 120 min, *i.e.*, >40% retained, were considered abnormal.

Statistical analysis

Paired *t* tests were used to determine significance of the changes in symptom scores and percentage of solid meal emptied at 120 min. A *p* value < 0.05 was considered significant.

RESULTS

Figure 2 summarizes the percentage of solid meal retained at 120 min, symptom scores, and the visually determined EGG frequencies in the six diabetic patients before and after treatment with domperidone for 6 months. At baseline or month 0, the mean percentage of meal retained at 120 min was $78.3 \pm 8.2\%$, range 62% to 88%. No patient emptied 50% of the meal in the 120-min period. Thus, $T_{1/2}$ values were not calculated. The mean symptom score at month 0 was 17.8 ± 5 , range 9-27. Nausea, vomiting, distention, or early satiety were rated severe by each patient. Esophageal symptoms such as heartburn or regurgitation were not present or were mild. EGG recordings at baseline showed that three patients had a flatline pattern (shown as zero frequency), two had 1- to 2-cpm EGG waves, and one patient had tachygastria (approximately 6-cpm frequency). No patient had a normal 3-cpm EGG pattern at baseline.

The mean percentage of meal retained at month 0 ($78.3\% \pm 8.2$) was not significantly different from the percentage retained after six months of domperidone therapy ($57.3\% \pm 27.7$, $p > 0.10$) (Fig. 2). Two patients (A and B) showed slightly increased gastric retention after 6 months of treatment. An overall trend toward improvement in gastric emptying was seen in the other four patients, but only patient C entered the normal range. The $T_{1/2}$ was >120 min in four patients, was abnormal (104 min) in one patient (D), and was normal (36 min) in one patient (C). On the other hand, each patient reported improvement in symptoms, and the

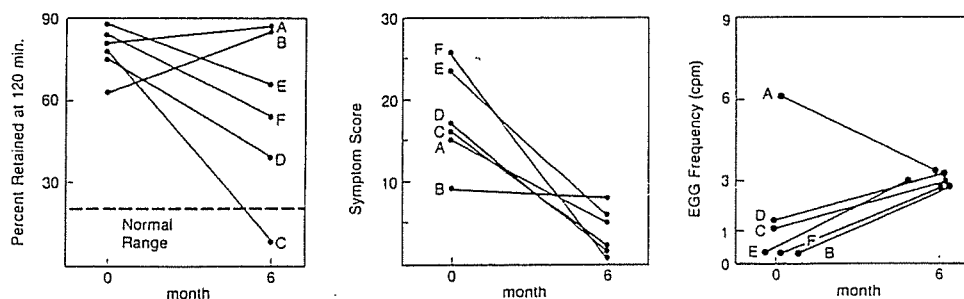


FIG. 2. Percentage of solid meal retained at 120 min after ingestion, gastrointestinal symptom scores, and EGG frequencies from patients with diabetic gastroparesis. Month 0 indicates baseline results. After 6 months of domperidone therapy, symptom scores improved significantly ($p < 0.01$), and normal 3-cpm EGG patterns developed in each patient (gastric emptying was not improved significantly).

mean symptom score decreased significantly from 17.8 at month 0 to 3.7 ± 2.9 at month 6 ($p < 0.01$).

During treatment with domperidone, gastric dysrhythmias resolved, and the normal 3-cpm EGG patterns were established, as determined by visual inspection and computer analysis of the EGG tracings. As shown in Figure 2, three patients with flatline pattern (patients B, E, and F) and one patient with tachygastria (patient A) converted to the normal 3-cpm EGG pattern. The 1- to 2-cpm EGG wave patterns in patients C and D predominated during treatment, but computer analysis of the EGG showed new peaks near 3 cpm which were not present at baseline in these two patients. No side effects or adverse reactions occurred during domperidone treatment.

EGGs and running spectral analyses (RSA) of 30 min of EGG signal from patient D are shown in Figure 3. The EGG signal shows a 1- to 2-cpm pattern at baseline. The baseline RSA of 30 min of EGG signal also shows large peaks in the 1- to 2-cpm range, and little or no 3-cpm peaks. After 6 months of domperidone treatment, the EGG shows less 1- to 2-cpm activity; the RSA also shows diminished 1- to 2-cpm peaks and a series of new peaks near 3 cpm. This patient's symptom score decreased from 17 to 1, with complete resolution of

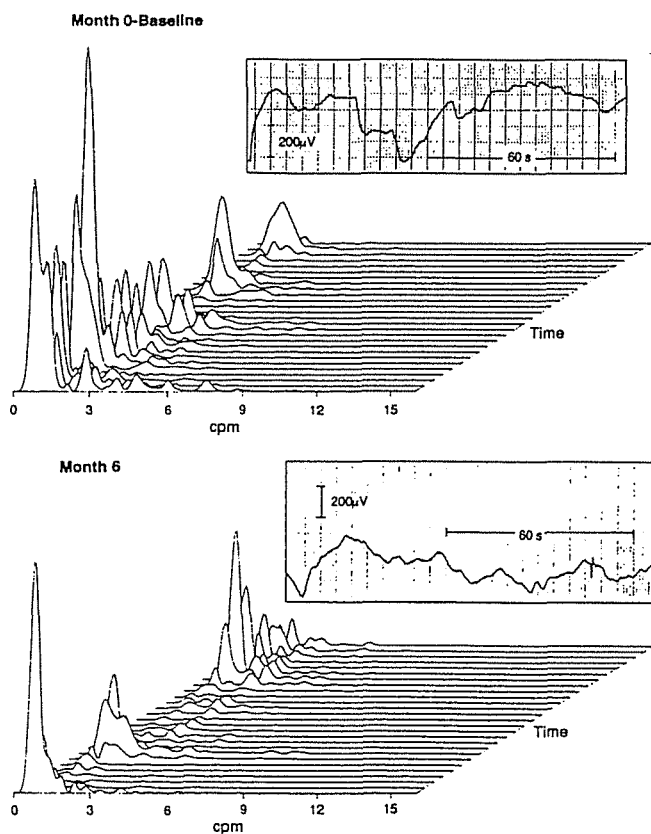


FIG. 3. Electrogastragrams (*top tracings*) and running spectral analyses (RSAs below each EGG) from patient D before and after domperidone. Note decreased 1- to 2-cpm activity and increased 3-cpm peaks at month 6. (See text for details.)

nausea, vomiting, and early satiety. The percentage of meal retained at 120 min approached the upper limits of normal (see Fig. 2).

Figure 4 shows EGGs and RSAs from 30 min of EGG signal recorded from patient E. The baseline EGG shows a flatline pattern with no obvious cyclical activity; the baseline RSA also showed no 3-cpm peaks and a distinct but transient frequency peak at 6 cpm. After 6 months of domperidone, the EGG signal showed a clear 3-cpm pattern, and the RSA also showed a predominance of 3-cpm peaks. This patient's symptom score decreased from 24 to 6, with resolution of nausea and vomiting. The percentage of meal retained at 120 min improved from 89% to 65%, but remained abnormal (see Fig. 2).

As shown in Figure 5, the EGG from patient F revealed a flatline pattern at month 0 (baseline), and the RSA from this 30-min baseline recording also showed no predominant frequency peaks. EGG recordings were obtained at 2-month intervals in this patient. After 2 months of domperidone, the patient's symptom score decreased from 26 to 9. A slight undulation in the EGG signal was present at month 2, and the 3-cpm EGG pattern became clearer over the subsequent months. By month 6, the patient had no upper GI symptoms, and a stronger 3-cpm EGG pattern was apparent, but the percentage of solid meal retained at 120 min remained abnormal at 56%. Domperidone

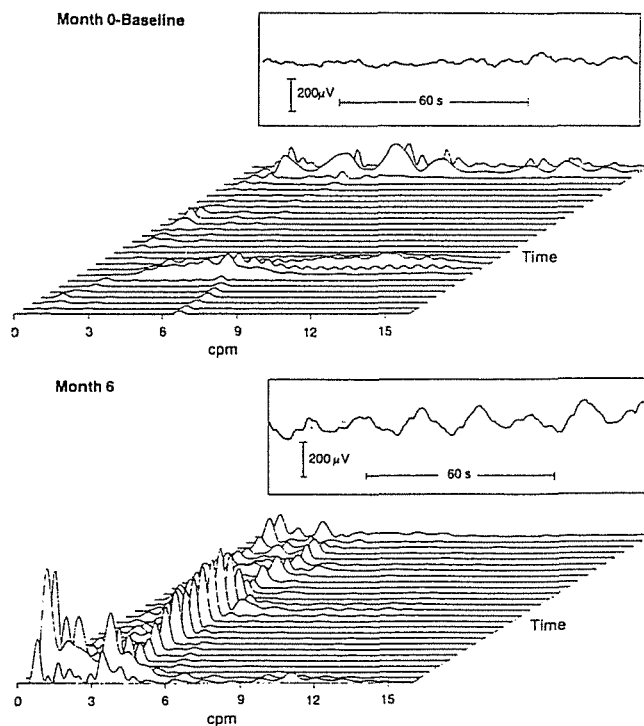


FIG. 4. Electrogastragrams (*top tracings*) and running spectral analyses (RSAs below each EGG) from patient E before and after domperidone. Note 3-cpm EGG waves and 3-cpm peaks at month 6. (See text for details.)

normal dramatic

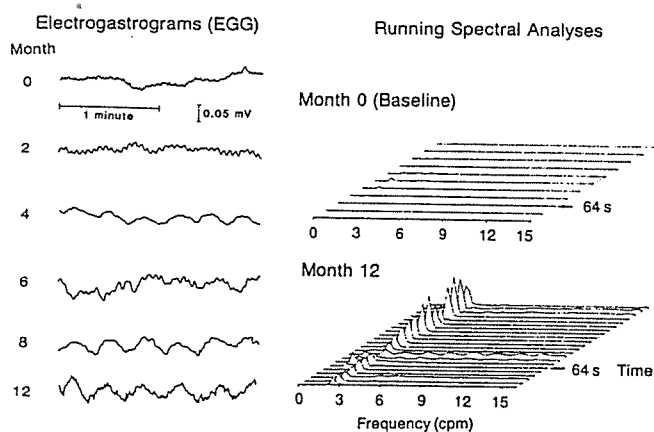


FIG. 5. Electrogastrograms and running spectral analyses from patient F. The EGG tracings show increasing clarity of 3-cpm activity during treatment. (See text for details.)

was continued, and EGGs were obtained sequentially in patient F for another 6 months. The 3-cpm pattern became progressively clearer in the EGG signal and in the RSA, as shown at month 12. At month 12 of treatment, however, the percentage of meal retained at 120 min remained markedly abnormal at 72%. After 24 months of domperidone treatment, the patient remained in a 3-cpm EGG pattern, had no upper GI symptoms, and the percentage of solids retained at 120 min was normal at 32%.

DISCUSSION

In the present study, gastric dysrhythmias and severe gastroparesis were documented at baseline in each diabetic patient. A relationship between gastric dysrhythmias and delayed gastric emptying was proposed previously on the basis of tachygastria recorded *in vivo* from gastric smooth muscle from a patient with idiopathic gastroparesis (14). Normal gastric peristalses are coordinated by gastric slow waves which emanate from the oral stomach and coordinate gastric peristalses (10, 11). In contrast to normal 3-cpm slow waves, human gastric dysrhythmias originate in the antrum (12, 13, 27). In the dog, tachygastrics usually propagate orally, whereas bradygastrics are frequently stationary (28, 29). Recent studies in the dog indicate that gastric emptying is diminished in the presence of gastric dysrhythmias (30). Taken together, these findings support the notion that human gastric dysrhythmias are electrophysiologic abnormalities which may contribute to gastroparesis in patients with long-standing diabetes mellitus.

Gastric dysrhythmias also are associated with symptoms of nausea and vomiting (12–14, 19–26). Results of the present study showed that gastric dysrhythmias are reduced or eliminated, normal 3-cpm gastric rhythms are restored, and upper GI symptoms are reduced significantly during long-term domperidone

treatment. On the other hand, effects of domperidone on gastric emptying results were highly variable in these same patients. Others have also shown significant symptom improvement with inconsistent improvement in the emptying of solids or liquids during treatment with metoclopramide, domperidone, and cisapride (4, 6, 8, 9). Loo *et al.* (6) found no correlation between gastric emptying of meals and upper GI symptoms. They concluded that symptoms of diabetic gastroparesis were not related to delayed emptying of the stomach, and suggested that other mechanisms should be considered in accounting for the symptoms attributed to gastroparesis. In the patients studied here, the reduction in gastric dysrhythmias and the emergence of normal 3-cpm EGG patterns were associated with improvement in symptoms, and represents a physiologic mechanism that may explain symptom improvement.

However, the establishment of normal fasting 3-cpm EGG patterns did not predict normal solid meal emptying. This discordance between normal 3-cpm myoelectrical activity and abnormal emptying results raises the possibility of “electromechanical dissociation” between the normal 3-cpm slow-wave activity and abnormal circular muscle and peristaltic activity which then results in gastroparesis. However, extragastric abnormalities such as pylorospasm and duodenal resistances also may have contributed to the persistence of delayed emptying in these diabetic patients with 3-cpm EGG activity (31). Simultaneous EGG and gastric emptying studies are needed to examine EGG rhythms during the actual emptying process.

Although the overall percentage of meal emptied at 120 min did not improve significantly after treatment, it is possible that the establishment of 3-cpm myoelectrical activity did contribute to more effective gastric contractions or gastroduodenal coordination, because increases in solid emptying were found in four of the six patients. Furthermore, a statistically significant effect of domperidone on gastric emptying may not be appreciated (type II error) because of the variable emptying results in these six patients. Spontaneous improvement in symptoms and myoelectrical rhythm is also a possibility in an open-label drug trial. However, these patients had chronic symptoms and had not responded previously to numerous medications. It seems unlikely that all of the patients would improve symptomatically and establish 3-cpm myoelectrical activity during this treatment period. In our opinion, the changes in myoelectrical activity and symptoms were more likely due to long-term domperidone treatment.

Domperidone, a peripheral antidopaminergic agent, enhances gastroduodenal contraction and coordination in a variety of experimental preparations (32). In patients with non-ulcer dyspepsia, however, short-term domperidone treatment decreased symptoms but did

not affect gastroduodenal contraction patterns (33). In the dog, domperidone increases antral contractility via enhanced activity of excitatory myenteric neurons (34) and decreases guinea pig antral relaxation induced by adrenergic agonists norepinephrine and phenylephrine (35). The slow improvement in gastric myoelectrical activity during domperidone therapy is similar to the long-term (12-month) drug treatment necessary to improve diabetic peripheral neuropathy (36). Contraction deficits in the antrum of diabetic patients with gastroparesis have been attributed to neuropathic abnormalities (37–39). Whether the domperidone effect on myoelectrical activity and emptying is related to dopamine receptors on neurogenic or myogenic sites in the stomach or receptors in the chemoreceptor trigger zone cannot be ascertained from the present studies. However, an “antiarrhythmic” action of domperidone associated with the shift from gastric dysrhythmias to 3-cpm gastric myoelectrical activity appeared to be more relevant to the reduction in upper GI symptoms than the “prokinetic” effect on gastric emptying rates, at least in these diabetic patients with severe gastroparesis.

APPENDIX

The recording channel was identified from which the clearest EGG signal was obtained. This EGG signal, previously stored on magnetic tape, was channeled to the A/D conversion board installed in the laboratory computer (Sperry IT, UNISIS, New York) where it was digitized at 4 Hz, a sampling rate which allows electrical activity from the heart, which may “leak” into the EGG signal, to be removed by digital filtering.

The digitized EGG signal was zero-centered and filtered to remove high-frequency (>15 cpm) and very low-frequency (<1 cpm) components which may alter the frequencies of interest in the raw signal. The filters used were fourth-order elliptical filters with a 200-millidB passband ripple. The low-pass filter had a high-frequency band edge at 0.20 Hz with an attenuation of –90 dB in the stopband. The high-pass filter had a high-frequency band edge at 0.015 Hz with required attenuation of –90 dB in the stopband.

After digital filtration, the time series was Fourier transformed and the spectral density estimates were calculated. The spectral analysis provided information concerning the frequencies contained in the signal. The spectral analysis used in these studies utilized a Hanning window and yielded spectra with frequency bin widths of 0.002084 Hz.

The EGG spectra calculated from a discrete time period, *i.e.*, a Fourier transformation, may be graphed or EGG spectra may be presented in a pseudo three-dimensional plot called a running spectral analysis (RSA). RSAs are constructed by performing spectral

analyses on successive segments of the digitized EGG signal, each of which is overlapped with preceding EGG segments. In RSAs presented within this work, *i.e.*, Figures 3, 4, and 5, each line on the RSA represents 4 min of EGG signal with a 75% overlap. Thus, each new and successive RSA line represents the frequencies present in 1 min of new EGG data added to the previous 3 min of EGG data.

ACKNOWLEDGMENT

The expert secretarial assistance of Susan Huntzinger is greatly appreciated.

Reprint requests: Kenneth L. Koch, M.D., Gastroenterology Division, University Hospital, Pennsylvania State University, Hershey, PA 17033.

REFERENCES

1. Rundles RW. Diabetic neuropathy: General review with report of 125 cases. *Medicine* 1945;24:111–60.
2. Wooten RL, Meriwether TW. Diabetic atony: A clinical study. *JAMA* 1961;176:68–73.
3. Zitomer BR, Gramm HF, Kozak GP. Gastric neuropathy in diabetes mellitus: Clinical and radiologic observations. *Metabolism* 1968;17:199–211.
4. Snape WJ, Battle WM, Schwartz SS, et al. Metoclopramide to treat gastroparesis due to diabetes mellitus. *Ann Intern Med* 1982;96:444–6.
5. Heer M, Muller-Duysing W, Benes I, et al. Diabetic gastroparesis: Treatment with domperidone—a double-blind, placebo-controlled trial. *Digestion* 1983;27:214–7.
6. Loo FD, Palmer DW, Soergel KH, et al. Gastric emptying in patients with diabetes mellitus. *Gastroenterology* 1984;86:485–94.
7. Horowitz M, Harding PE, Chaterton BE, et al. Acute and chronic effects of domperidone on gastric emptying in diabetic autonomic neuropathy. *Dig Dis Sci* 1985;30:1–9.
8. Schade RR, Dugas ML, Lhotsky DM, et al. Effect of metoclopramide on gastric liquid emptying in patients with diabetic gastroparesis. *Dig Dis Sci* 1985;30:101–15.
9. Horowitz M, Maddox A, Harding PE, et al. Effect of cisapride on gastric and esophageal emptying in insulin-dependent diabetes mellitus. *Gastroenterology* 1987;92:1899–907.
10. Meyer JE. Motility of the stomach and gastroduodenal junction. In: Johnson LR, ed. *Physiology of the gastrointestinal tract*. New York: Raven Press; 1987:393–410.
11. Hinder RA, Kelly KA. Human gastric pacesetter potential: Site of origin, spread and response to gastric transection and proximal gastric vagotomy. *Am J Surg* 1977;133:29–33.
12. You CH, Lee KY, Chey WY, et al. Electrogastrographic study of patients with unexplained nausea, bloating and vomiting. *Gastroenterology* 1980;79:311–4.
13. You CH, Lee KY, Chey WY. Gastric electromyography in normal and abnormal states in humans. In: Chey WY, ed. *Functional Disorders of the Digestive Tract*. New York: Raven Press, 1983:167–73.
14. Telander RL, Morgan KG, Kreulan DL, et al. Human gastric atony with tachygastric and gastric retention. *Gastroenterology* 1978;75:497–501.
15. Smout AJPM, van der Schee EJ, Grashuis JL. What is measured in electrogastrography? *Dig Dis Sci* 1980; 25:179–87.
16. Nelsen TS, Kohatsu S. Clinical electrogastrography and its relationship to gastric surgery. *Am J Surg* 1968;116:215–22.
17. Brown BH, Smallwood RH, Duthie HL, et al. Intestinal smooth muscle electrical potentials recorded from surface electrodes. *Med Biol Eng* 1975;13:97–103.
18. Hamilton JW, Bellahsene BE, Reichelderfer M, et al. Human

- electrogastrograms. Comparison of surface and mucosal recordings. *Dig Dis Sci* 1986;31:33-9.
19. Abell TL, Malagelada JR. Glucagon-evoked gastric dysrhythmias in humans shown by an improved electrogastrographic technique. *Gastroenterology* 1985;88:1932-40.
 20. Bellahsene BE, Schimer BD, Updike OL, et al. Validation of the transcutaneous electrogastrogram (EGG) using intraoperatively implanted electrodes in humans. *Gastroenterology* 1987;92:1313 (abstract).
 21. Geldof H, van der Schee EJ, van Blankenstein M, et al. Electrogastrographic study of gastric myoelectrical activity in patients with unexplained nausea and vomiting. *Gut* 1986;27:799-808.
 22. Koch KL, Stern RM, Vasey MW, et al. Gastric dysrhythmias and nausea of pregnancy. *Dig Dis Sci* 1987;32:917 (abstract).
 23. Abell TL, Malagelada J-R, Lucas AR, et al. Gastric electromechanical and neurohormonal function in anorexia nervosa. *Gastroenterology* 1987;93:958-65.
 24. Abell TL, Camilleri M, Malagelada J-R. High prevalence of gastric electrical dysrhythmias in diabetic gastroparesis. *Gastroenterology* 1985;88:1299 (abstract).
 25. Stern RM, Koch KL, Leibowitz HW, et al. Tachygastric and motion sickness. *Aviat Space Environ Med* 1985;56:1074-7.
 26. Stern RM, Koch KL, Stewart WR, et al. Spectral analysis of tachygastric recorded during motion sickness. *Gastroenterology* 1987;92:92-7.
 27. Stoddard CJ, Smallwood RH, Duthie HL. Electrical arrhythmias in the human stomach. *Gut* 1981;22:705-12.
 28. Kim CH, Azpiroz F, Malagelada J-R. Characteristics of spontaneous and drug-induced gastric arrhythmias in a chronic canine model. *Gastroenterology* 1986;90:421-7.
 29. Kim CH, Zinsmeister AR, Malagelada J-R. Mechanisms of canine gastric dysrhythmia. *Gastroenterology* 1987;92:993-9.
 30. Kim CH, Zinsmeister AR, Malagelada J-R. Effect of gastric dysrhythmias on postcibal motor activity of the stomach. *Dig Dis Sci* 1988;33:193-9.
 31. Mearin F, Camilleri M, Malagelada J-R. Pyloric dysfunction in diabetics with recurrent nausea and vomiting. *Gastroenterology* 1986;90:1919-25.
 32. Brogden RN, Carmine AA, Heel RC, et al. Domperidone. A review of its pharmacological activity, pharmacokinetics and therapeutic efficacy in the symptomatic treatment of chronic dyspepsia and as an anti-emetic. *Drugs* 1982;24:360-400.
 33. Davis RH, Clench MH, Mathias JR. Effects of domperidone in patients with chronic unexplained upper gastrointestinal symptoms: A double-blind, placebo-controlled study. *Dig Dis Sci* 1988;33:1505-11.
 34. Fujii K, Takasugi S, Toki N. Excitatory response of gastric movement by domperidone and the mechanism involved. *Drug Res* 1980;30:640-4.
 35. Sahyoun HA, Costall B, Naylor RJ. On the ability of domperidone to selectively inhibit catecholamine-induced relaxation of circular smooth muscle of guinea pig stomach. *J Pharm Pharmacol* 1982;34:27-33.
 36. Sima AAF, Bril V, Nathaniel V, et al. Regeneration and repair of myelinated fibers in sural-nerve biopsy specimens from patients with diabetic neuropathy treated with sorbinil. *N Engl J Med* 1988;319:548-55.
 37. Malagelada J-R, Rees WDW, Mazzotta LJ, et al. Gastric motor abnormalities in diabetic and postvagotomy gastroparesis: Effect of metoclopramide and bethanechol. *Gastroenterology* 1980;78:286-93.
 38. Fox S, Behar J. Pathogenesis of diabetic gastroparesis—a pharmacologic study. *Gastroenterology* 1980;78:757-63.
 39. Camilleri M, Brown ML, Malagelada J-R. Relationship between impaired gastric emptying and abnormal gastrointestinal motility. *Gastroenterology* 1986;91:94-9.