

## Abnormalities of the Electrogastrogram in Globus Pharyngeus

HIROHITO NISHINO<sup>1</sup>, TORU OHASHI<sup>1</sup>, TAKESHI UMEHARA<sup>2</sup>, MUTSUMI KENMOCHI<sup>1</sup>, TOMOYUKI OKADA<sup>2</sup> and IZUMI KOIZUKA<sup>2</sup>

From the Departments of Otolaryngology, <sup>1</sup>St. Marianna University Yokohama City Seibu Hospital, Yokohama, Japan and <sup>2</sup>St. Marianna University School of Medicine, Kawasaki, Japan

**Nishino H, Ohashi T, Umehara T, Kenmochi M, Okada T, Koizuka I.** *Abnormalities of the electrogastrogram in globus pharyngeus.* Acta Otolaryngol 2004; Suppl 553: 117–121.

There appear to be multiple indicators for the presence of globus pharyngeus. We have assumed that patients with abnormal gastric motility can be included among those suffering from globus pharyngeus. Gastric motility can be examined non-invasively using the electrogastrogram (EGG). In this study, 32 patients (22 females, 10 males; mean age  $55 \pm 13$  years) with symptoms of globus pharyngeus consented to EGG recording. The EGGs of asymptomatic healthy adults (6 females, 10 males; mean age  $28 \pm 5$  years) were obtained as controls. No significant statistical difference was found in any of the measurement parameters between the two groups. However, we found that 9.4% of patients with globus pharyngeus exhibited abnormal gastric myoelectrical activity as measured by the EGG. This suggests that a small proportion of patients who complain of globus pharyngeus have abnormal gastric motility. *Key words:* electrogastrography, gastric motility, globus pharyngeus.

### INTRODUCTION

Patients with symptoms of globus pharyngeus are frequently encountered by ENT clinicians. However, multiple factors are thought to cause these symptoms, including gastroesophageal reflux and chronic gastritis. Abnormal gastric motility is considered to be a cause of chronic gastritis (1–7) and gastroesophageal reflux disease (8, 9). Therefore, we suppose that patients with abnormal gastric motility can be included among those suffering from globus pharyngeus. Symptoms of globus pharyngeus that manifest as abnormal gastric motility might be improved by medication with trimebutine maleate, which has been found to be effective in controlling symptoms in some patients with abnormal gastric motility (10).

The electrogastrogram (EGG) is a non-invasive clinical test that records gastric myoelectrical activity for the examination of gastric motility. In 1922, Alvarez (11) made the first recordings of gastric electrical activity from the surface of the body. The recording of these signals presents several difficulties: (i) the voltages induced on the abdominal wall are very low; (ii) interpretation of the recorded data is difficult; and (iii) the relationship between the EGG and gastric motility is unclear. However, recent developments in filter technology and analysis techniques have made it possible to record and analyze EGGs in clinical applications (1–4).

We recorded EGGs in patients complaining of globus pharyngeus in order to determine the proportion of cases who presented abnormal gastric myoelectrical activity.

### MATERIAL AND METHODS

#### Subjects

The group with symptoms of globus pharyngeus comprised 32 patients (22 females, 10 males; mean age  $55 \pm 13$  years) who presented complaining of symptoms of globus pharyngeus at St. Marianna University Yokohama City Seibu Hospital between June and August 2000, and who consented to EGG recording. All patients underwent examinations of the nasal cavity, epipharynx, larynx and pharyngoesophageal junction using a soft-fiber endoscope, and radiography with barium ingestion to confirm that no organic abnormalities were present. The EGGs of asymptomatic healthy adults (6 females, 10 males; mean age  $28 \pm 5$  years) were obtained as controls. The care of the human subjects used in this study was approved by the Ethical Committee of St. Marianna University Yokohama City Seibu Hospital. Informed consent was obtained from all participants according to the Declaration of Helsinki.

#### Methods

A portable EGG recorder (Nipro electrogastrograph; Nipro, Osaka, Japan) was used. Electrodes were placed as follows: the reference electrode (R) was placed on the midpoint between the xiphoid process and the umbilicus; electrode E1 on the midpoint of the right clavicle line between the xiphoid process and electrode R; electrode E2 on the midpoint of the left clavicle line between the xiphoid process and electrode R; electrode E3 on the midpoint of the right clavicle line between electrode R and the umbilicus; and electrode E4 on the midpoint of the left clavicle line between electrode R and the umbilicus (Fig. 1). The

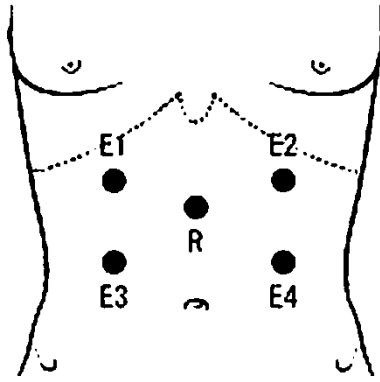


Fig. 1. Electrode positions.

EKG was recorded after fasting: for 1 h in the fasting state and for 1 h in the fed state after taking 15 min to ingest a standard hospital meal. Electrical activity at electrode E2 was recorded for the evaluation of the EKG, as its position is close to the great curvature in one-third of the upper gastric corpus, where the pacemaker for gastric myoelectrical activity is thought to exist. In this study we did not use electrodes E1, E3 or E4.

The EKG data were recorded on a PC, and the spectra were obtained using fast Fourier transformation. Several EKG parameters were statistically compared between the patient and control groups using the Mann-Whitney U-test.  $p < 0.05$  was considered significant.

Electrical signals having frequencies in the range 2.0–4.0 cycles per minute (cpm) were defined as normal. Activity below the normal range was termed bradygastria, and activity above the normal range was termed tachygastria. A normal EKG was defined as normal electrical activity occurring for  $> 70\%$  of the

recording time (5, 6), and the EKG was evaluated in both pre- and postprandial stages. The amplitude was also considered, with a ratio of post- to preprandial power of  $> 1$  being regarded as normal (1–4). Cases that presented abnormal frequency values in the pre- and postprandial periods and an abnormal amplitude power ratio were judged as having abnormal gastric myoelectrical activity and consequently gastric motility disorder.

## RESULTS

Examples of normal and abnormal EKGs are shown in Figs 2 and 3, respectively. The electrogastrographic data for both groups are given in Table I. No significant statistical difference was found in any of the measurement parameters between the two groups (Table I).

None of those in the control group exhibited abnormal myoelectrical activity, compared to 9.4% (3/32) of those in the patient group (Table II).

## DISCUSSION

### *Electrogastrography*

The EKG can comprise electrical activity of smooth muscle in the stomach, consisting of both slow-wave and spiking potentials. Slow-wave potentials correspond to persistent action potentials, and are thought to originate from a region near the junction of the proximal third of the gastric corpus along the great curvature. This potential is characterized by regularity, recurrent presentation and circumferential propagation distally toward the pylorus with increasing velocity and amplitude. The slow wave is thought to have a frequency of about 3 cpm, and to control the rhythm and propagation of contractions. Spiking

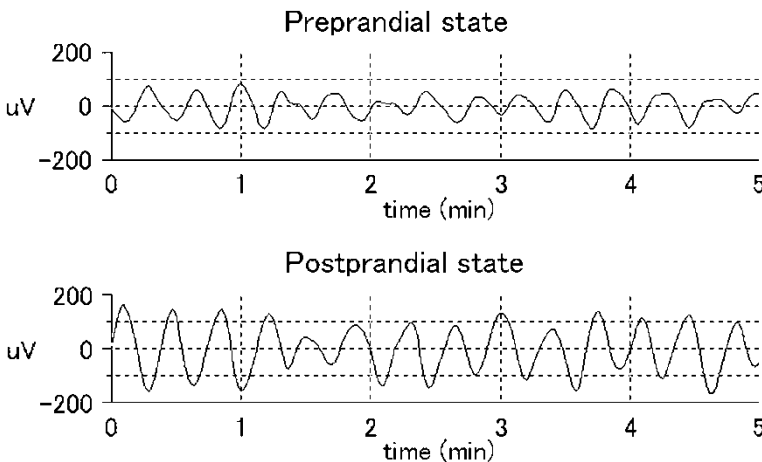


Fig. 2. Normal EKG waveforms (preprandial state: 2.77 cpm, normal = 92%; postprandial state: 3.04 cpm, normal = 97%; power ratio = 1.46). Response waveforms in pre- and postprandial states (5 min each) are presented, showing that normal electrical activity with frequencies of 2–4 cpm was present, and that the amplitude increased by  $> 50 \mu\text{V}$  after eating.

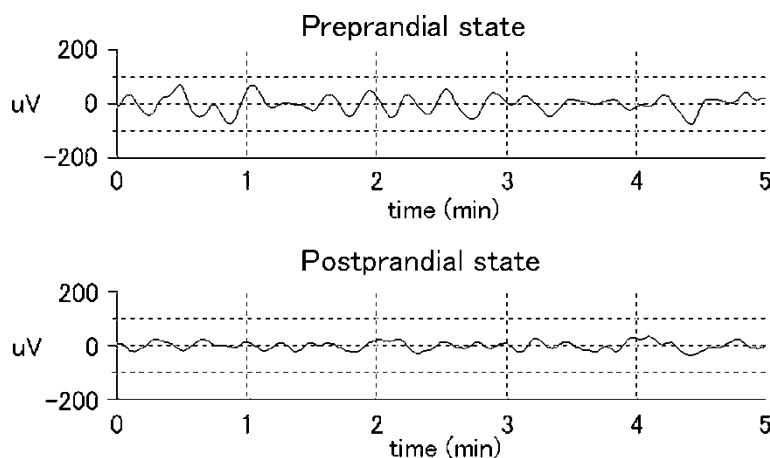


Fig. 3. Abnormal EGG waveforms (preprandial state: 2.41 cpm, normal = 67%; postprandial state: 2.40 cpm, normal = 58%; power ratio = 0.49). Response waveforms in pre- and postprandial states (5 min each) are presented, showing a lower incidence of the frequency of the electrical activity occurring within the normal range in both states. The amplitude of the EGG decreased after eating.

potentials are considered to correlate with antral contractions: when a slow wave is followed by spikes, an antral contraction occurs. Previous studies (1) have shown that cutaneous electrodes may dominantly pick up the rhythm of the slow wave rather than recording spikes, because the electrical spikes appear irregularly in various regions of the stomach and have various frequencies and random phases. A number of studies (12) have documented that EGG recordings from the abdominal surface are consistent with those obtained from stomach smooth muscle or serous membrane. The reproducibility of the EGG recording has been confirmed (1), with similar waveforms being recorded on separate days. Furthermore, it was also reported that the EGG is not significantly affected by age or gender (13, 14).

The EGG yields information on the frequency and amplitude of electrical activity of the stomach muscles. EGGs that include frequencies within the normal range (2–4 cpm) for > 70% of the time are defined as normal (5, 6). Dysrhythmias are classified into rapid (tachygastria; > 4 cpm), slow

(bradygastria; < 2 cpm) or mixed (bradytachyarrhythmia) patterns (1–4), and are considered to indicate abnormal gastric myoelectrical activity. The amplitude of the EGG may reflect the gastric myoelectrical activity of stomach muscle. As the absolute amplitude of the signal may be affected by the patient's habitus and electrode location, we examined the ratio of the amplitudes in the post- and preprandial conditions. A value greater than one was indicative of a true postprandial increase in the electrical activity of the stomach (2–4). Some authors (15) have considered only the response frequency in EGG examinations. However, the role of the EGG as a diagnostic tool in gastric motor disorders is still under debate. In this study, we judged an EGG that showed abnormalities of both frequency and power ratio as being abnormal.

#### *Correlation between globus pharyngeus and abnormal gastric myoelectrical activity*

Some patients suffer from upper gastrointestinal symptoms even though they have no organic disease. It was reported (5–8) that in some of these patients

Table I. EGG parameters in the control and patient groups. Results are expressed as mean  $\pm$  SD

Parameter	Patients	Controls
Preprandial		
Dominant frequency (cpm)	2.92 $\pm$ 0.38	2.73 $\pm$ 0.15
Bradygastria (%)	11 $\pm$ 13	9 $\pm$ 7
Normal (%)	86 $\pm$ 19	90 $\pm$ 7
Tachygastria (%)	3 $\pm$ 10	0 $\pm$ 1
Postprandial		
Dominant frequency (cpm)	2.86 $\pm$ 0.38	2.76 $\pm$ 0.26
Bradygastria (%)	21 $\pm$ 19	18 $\pm$ 17
Normal (%)	79 $\pm$ 19	81 $\pm$ 18
Tachygastria (%)	1 $\pm$ 4	1 $\pm$ 2
Power ratio	1.33 $\pm$ 0.88	1.3 $\pm$ 0.79

Table II. Results of the EGG test

Group	Normal	Abnormal
Patients	29	3
Controls	16	0

the development and spread of the functional examination of gastrointestinal motility has made it possible to detect dysfunctional gastrointestinal motility. The stagnation of food and secretions in the stomach due to abnormal gastric motility may cause symptoms of discomfort, such as nausea and vomiting. Additionally, such a pathologic state is also considered to give rise to functional dyspepsia, diabetic gastroparesis and indefinite epigastric complaints due to autonomic imbalance (6, 7). It has been suggested in some reports (8, 9) that gastroesophageal reflux disease (GERD) may also result from the stagnation of food in the stomach. Upper gastrointestinal disease, diabetes and autonomic imbalance are responsible for the symptoms of globus pharyngeus. The EGG was abnormal in patients with functional dyspepsia (5–7). In patients with GERD and in controls, a significant inverse correlation between fed electrogastric power and gastric emptying time was found (8). Therefore, we assume that abnormal gastrointestinal motility is responsible for the generation of these symptoms. However, no statistically significant difference was found in EGG parameters between the control and patient groups in the present study (Table I). We therefore suggest that globus pharyngeus may have multifactorial causes (i.e. stress or climacteric), and hence that non-organic diseases of the gastrointestinal duct become one of the pathogenetic factors for globus pharyngeus. We assume that the low rate of abnormal EGG found in this study reflects the fact that our patients did not have abnormal gastrointestinal motility.

We found that 9.4% of our globus pharyngeus patient group had gastric electrical abnormalities (Table II). These cases may indicate a correlation between globus pharyngeus and abnormal gastric myoelectrical activity, but the direction of this correlation (i.e. whether abnormal gastric motility causes globus pharyngeus or vice versa) is still unclear. If the correlation between abnormal gastric motility and globus pharyngeus is verified, then the symptoms of globus pharyngeus that appear as abnormal findings in EGG tests might be improved by medication with trimebutine maleate. Trimebutine maleate, a prokinetic drug, acts directly on the smooth muscles of the digestive tract

and is widely used clinically as a regulator of gastrointestinal motility (10). We plan to study this in the future.

#### ACKNOWLEDGEMENTS

We thank Mrs Hiromi Hatakeyama and Mrs Naoko Okamoto for their support in collecting the data.

#### REFERENCES

1. Chen JD, McCallum RW. Clinical applications of electrogastronomy. *Am J Gastroenterol* 1993; 88: 1324–36.
2. Camilleri M, Hasler WL, Parkman HP, Quigley EM, Soffer E. Measurement of gastrointestinal motility in the GI laboratory. *Gastroenterology* 1998; 115: 747–62.
3. Verhagen MA, Van Schelven LJ, Samsom M, Smout AJ. Pitfalls in the analysis of electrogastronomic recordings. *Gastroenterology* 1999; 117: 453–60.
4. Parkman HP, Harris AD, Krevsky B, Urbain JL, Maurer AH, Fisher RS. Gastrointestinal motility and dysmotility: an update on techniques available for evaluation. *Am J Gastroenterol* 1995; 90: 869–92.
5. Leahy A, Besherdas K, Clayman C, Mason I, Epstein O. Abnormalities of the electrogastronomic in functional gastrointestinal disorders. *Am J Gastroenterol* 1999; 94: 1023–8.
6. Chen JD, Lin Z, Pan J, McCallum RW. Abnormal gastric myoelectrical activity and delayed gastric emptying in patients with symptoms suggestive of gastroparesis. *Dig Dis Sci* 1996; 41: 1538–45.
7. Pfaffenbach B, Adamek RJ, Bartholomaeus C, Wegener M. Gastric dysrhythmias and delayed gastric emptying in patients with functional dyspepsia. *Dig Dis Sci* 1997; 42: 2094–9.
8. Cucchiara S, Salvia G, Borrelli O, Ciccimarra E, Az-Zeqeh N, Rapagiolo S, et al. Gastric electrical dysrhythmias and delayed gastric emptying in gastroesophageal reflux disease. *Am J Gastroenterol* 1997; 92: 1103–8.
9. Koufman JA. The otolaryngologic manifestations of gastroesophageal reflux disease (GERD): a clinical investigation of 225 patients using ambulatory 24-hour pH monitoring and an experimental investigation of the role of acid and pepsin in the development of laryngeal injury. *Laryngoscope* 1991; 101(Suppl 53): 1–78.
10. Kamiya T, Nagao T, Andou T, Misu N, Kobayashi Y, Hirako M, et al. Effects of trimebutine maleate on gastric motility in patients with gastric ulcer. *J Gastroenterol* 1998; 33: 823–7.
11. Alvarez WC. The electrogastronomic and what it shows. *J Am Med Assoc* 1922; 78: 1116–8.
12. Mintchev MP, Otto SJ, Bowes KL. Electrogastronomy can recognize gastric electrical uncoupling in dogs. *Gastroenterology* 1997; 112: 2006–11.
13. Parkman HP, Harris AD, Miller MA, Fisher RS. Influence of age, gender, and menstrual cycle on the

- normal electrogastrogram. *Am J Gastroenterol* 1996; 91: 127–33.
14. Pfaffenbach B, Adamek RJ, Kuhn K, Wegener M. Electrogastrography in healthy subjects. Evaluation of normal values, influence of age and gender. *Dig Dis Sci* 1995; 40: 1445–50.
  15. Mintchev MP, Kingma YJ, Bowes KL. Accuracy of cutaneous recordings of gastric electrical activity. *Gastroenterology* 1993; 104: 1273–80.

Address for correspondence:  
Hirohito Nishino, MD  
Department of Otolaryngology  
St. Marianna University School of Medicine  
2-16-1, Sugao, Miyamae-ku  
Kawasaki 216-8511  
Japan  
Tel.: +81 44 977 8111  
Fax: +81 44 976 8748  
E-mail: hnishino@marianna-u.ac.jp